

Section 5

LECTURE

Pathology of the Esophagus and Stomach

Non-Neoplastic Diseases of the Esophagus and Stomach

Part I: Esophagus

I. ANATOMY

In the adult, esophagus is an approximately 25 cm long tubular structure located in the posterior mediastinum. It begins below the pharynx at the level of the sixth cervical vertebra and extends below the diaphragm for 1-2 cm before joining the stomach.

II. HISTOLOGY

A. Mucosa

1. *Surface epithelium*: non-keratinized stratified squamous epithelium.
2. *Lamina propria*: variably present, scattered mucin-producing glands are located at both ends of the organ.
3. *Muscularis mucosae*: longitudinal and circular layers of smooth muscle with elastic fibers.

B. Submucosa

Like the muscularis mucosae, the submucosa of the esophagus contains numerous elastic fibers. This feature, plus the numerous mucosal folds, allows the esophagus to distend greatly during the passage of large food fragments. The submucosa contains the esophageal glands proper: mucin- and perhaps bicarbonate-producing. These serve as a source of lubrication for the luminal surface, and may be viewed as tiny salivary-type glands. The submucosa also contains several vertical venous channels which connect the portal and systemic venous systems via the left gastric and azygous systems, respectively. This venous pattern is of great importance in the development of esophageal varices (will be discussed later).

C. Muscularis propria

Generally organized into typical inner circular and outer longitudinal layers, but the direction of fibers, especially in the inner layer, varies, and may be oblique or spiral. In humans, the type of muscle cell varies in different areas. In the upper one-third it is skeletal muscle, and in the lower two-thirds, smooth muscle. Although histologically of two types, the esophageal muscularis functions as an integrated unit. Both muscle types are under vagal control and their nutrient blood supplies are essentially the same.

D. Adventitia

The esophagus is not covered with a serosa, and there is direct communication between the esophageal connective tissue and mediastinal structures, especially posteriorly. There are numerous lymph nodes in adventitia, with extensive lymphatic communications among them.

III. PHYSIOLOGY

Sphincters located at the upper and lower ends of the esophagus normally keep the esophagus free of material between swallows. The *upper esophageal sphincter* is anatomically identifiable at the level of the cricopharyngeus muscle located at the pharyngo-esophageal junction. Normally contracted, this sphincter relaxes with swallowing, then re-contracts. The cricopharyngeus muscle fibers form a somewhat loose interlacing network posteriorly, resulting in some degree of mural weakness. Abnormally high contraction forces and increased intraluminal pressure probably contribute to the development of diverticula at this site (see below). Unlike other GI sphincters (pylorus, anus) which are formed by smooth muscle in the wall, this sphincter is formed of extrinsic skeletal muscle. Immediately below the cricopharyngeus, there is a narrow

esophageal band of somewhat increased intraluminal pressure suggestive of an intrinsic smooth muscle sphincter effect, but the existence of such a sphincter has not been proven.

The *lower esophageal sphincter (LES)* is not anatomically identifiable but functionally is represented by a high pressure zone involving the distal 2-3 cm of the esophagus. Physiologic role of this sphincter is to prevent reflux of gastric contents into the esophagus by separating positive intragastric pressure from negative intra-esophageal pressure. Like the upper sphincter, LES is normally contracted, but relaxes during swallowing. The smooth muscle in the LES area is more sensitive to hormonal and pharmacological agents than the rest of the esophageal musculature. Serum levels of active Gastrin and other hormones such as Vasoactive Intestinal Peptide (released from the gastric antrum) may be important in determining the resting strength of the LES. Cholinergic agents increase LES strength, but whether these agents act directly through neurological mechanisms or indirectly by influencing hormone release, is not known.

Pressure in the LES can be finely controlled, increasing as the intragastric pressure increases. A failure of relaxation with swallowing is related to the pathogenesis of *achalasia*. Solid foods in the esophagus elicit a propagated ring contraction (peristalsis) which sweeps down the esophagus, "wiping" it free of food.

IV. CONGENITAL DISORDERS

A. Esophageal atresia and tracheoesophageal fistula were discussed in the embryology lecture.

B. Pulmonary sequestration and bronchogenic (retention) cysts are due to developmental diverticula arising from distal esophagus or proximal stomach. These form accessory or "sequestered" bronchi and pulmonary tissue which are not connected to the normal lungs. Cystic masses lined by bronchial epithelium, and termed bronchogenic or retention cysts, can also develop. These may be present in the wall of the esophagus or in the mediastinum. Clinically, they may present as masses, or if there is a residual connection with the esophagus, the cyst or sequestered tissue may become inflamed and infected.

C. Esophageal webs and rings are redundant masses of esophageal wall that project into the lumen. They may consist of mucosa alone or also have muscularis. The more common form is located in distal esophagus, just above the junction with the stomach. Most webs and rings are asymptomatic, but they may be the cause of obstruction with large pieces of food. A rare form occurs in proximal esophagus, and is associated with iron deficiency anemia (Plummer-Vinson Syndrome) and increased incidence of squamous cell carcinoma.

V. MOTOR AND MECHANICAL DISORDERS

A. Diverticula (Figure 1)

Pulsion diverticula are outpouchings of the mucosa through intrinsically weak areas of the esophageal wall. Two major forms are pharyngo-esophageal (Zenker's), located posteriorly at level of crico-pharyngeous muscle; and epiphrenic, at lower end just above diaphragm. *Traction* diverticula develop from pulling of the esophageal wall by extrinsic processes, usually inflammatory and involving the pulmonary hilar or mediastinal lymph nodes. Diverticula act as reservoirs for food leading to stasis, infection and ulceration, with complications of hemorrhage and perforation. Large pulsion diverticula may also compress and obstruct the esophagus.

B. Fistulas and stenoses

Fistulas may be congenital (discussed earlier) or acquired as a result of perforation from trauma, severe esophagitis or tumor. Complications include mediastinitis and pneumonitis. *Stenoses* may be congenital (atresias, webs/rings) or occur secondary to inflammatory stricture, tumor, or primary disorder of connective

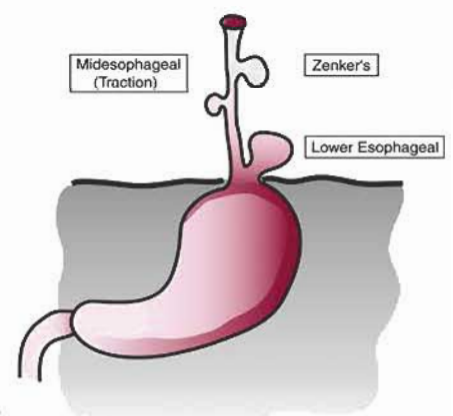
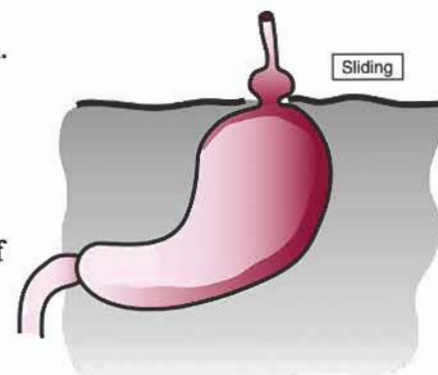


FIGURE 1. Classification of esophageal diverticula.

tissue (e.g., scleroderma). Stenoses typically result in dysphagia, first for solid foods and later for liquids.

C. Hiatal hernia (Figure 2)

A common disorder, perhaps present to some degree in 50% of the population. It represents protrusion of stomach through a diaphragmatic defect either in direct continuity with esophagus (axial) or in adjacent position (para-esophageal). Hiatal hernia is often blamed for symptoms such as heartburn, but studies have demonstrated that this should be attributed instead to sphincter dysfunction and reflux esophagitis. Rare forms of large congenital diaphragmatic hernias occur in infants, resulting in displacement of many abdominal organs into the chest cavity, and compression of the mediastinal structures.



D. Achalasia

Achalasia is a defect in esophageal peristalsis and relaxation of lower esophageal sphincter. Equivalent condition occurs as late complication of Chagas' disease (an infection by the protozoa *Trypanosoma cruzi*) which is endemic in parts of South America, particularly in Brazil (it is thought that toxins of the organism damage the neural elements in the esophageal wall). In the infectious form, there is often involvement of other portions of the digestive tract and other hollow viscera such as the urinary bladder. Pathologically achalasia presents as persistent narrowing of distal esophagus. Proximal to this, there is marked dilation and thickening of the wall related to the chronic obstruction. There is a patchy loss of neural elements, but this may also be a secondary effect. Late effects include an increased incidence of squamous cell carcinoma.

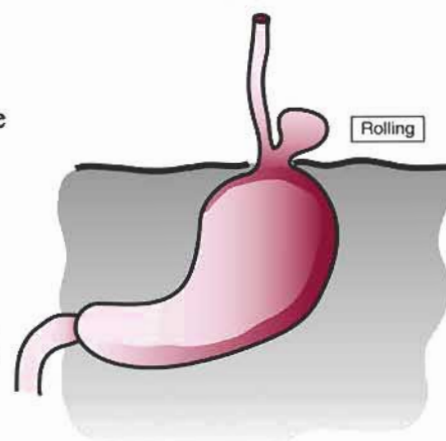


FIGURE 2. Types of hiatal hernias.

E. Systemic sclerosis (Scleroderma)

Scleroderma is a disorder of unknown etiology, characterized by progressive sclerosis (fibrosis) and microvascular lesions in many tissues and organs, including the skin, GI tract, lungs, kidneys, etc. Esophageal involvement is common, but often asymptomatic. Pathologically, the earliest lesion is a focal loss of muscularis propria, which can be revealed by manometry showing isolated regions without peristaltic activity. Symptoms appear when there is involvement of the LES, resulting in reflux esophagitis. Later problems include inflammatory fibrotic stricture from the persistent esophagitis.

F. Other neuro-muscular disorders

There is a host of other conditions due to primary damage of the nerves (neuropathies), proximal striated muscle (Myasthenia Gravis, Muscular Dystrophies), ganglia or smooth muscle in wall (Hollow Visceral Myopathy). Clinically, they may lead to functional obstruction (termed "pseudo-obstruction") and dysphagia. Later effects are due to muscle damage from disease or therapeutic dilation, resulting in poor peristalsis and/or sphincter closure, favoring the development of peptic esophagitis.

IV. VASCULAR DISORDERS

A. Esophageal varices

As a consequence of the porto-systemic shunt through the esophageal venous system, dilated large veins in wall of esophagus occur secondary to *portal venous hypertension* of any cause (usually liver cirrhosis). Varices are usually present in gastric wall as well. The submucosal veins may protrude into the lumen and are readily visualized by x-ray or endoscopy. A major complication is rupture of the veins and massive hemorrhage into esophageal lumen.

B. Ischemic disease

Infarction of the esophagus due to vascular insufficiency is extremely rare, thanks to its dual circulation from bronchial and celiac arteries. In conditions with marked esophageal dilatation, with pressure on the mucosa, venous stasis and secondary ischemic damage may occur.

C. **Vasculitis and vascular malformations** are rare and will not be discussed.

V. INFLAMMATORY DISORDERS (ESOPHAGITIS)

A. Infections of esophagus

Relatively uncommon, infections of the esophagus are due mainly to opportunistic agents such as herpes simplex, cytomegalovirus, and candida. They are seen more often in patients with immunosuppression, diabetes mellitus, or AIDS. Pathologically, there is focal or diffuse ulceration, with marked inflammation. Specific diagnosis provided by mucosal biopsy and cytologic smears to see viral inclusions or fungi.

B. Corrosive esophagitis

An uncommon entity, due to ingestion of toxic chemicals, particularly alkali. Results in extensive destruction of the mucosa. Late effects include stricture and possible increased incidence of tumors. Histopathology is non-specific.

C. Reflux (peptic) esophagitis

Gastroesophageal reflux (GER) is the most common cause of esophagitis. Practically all people experience occasional episodes of reflux, and it is suspected that the disorder might affect 5% of our population. Esophagitis is due to incompetence of the LES and/or faulty esophageal motility, resulting in reflux of the gastric contents into the esophagus, and poor clearance of acid-pepsin (and, less often, bile), and mucosal injury. Esophagitis can also be due to frequent vomiting associated with Bulimia.

Pathology of GER may be divided into early and late phases. Early changes include diffuse mucosal inflammation and epithelial cell necrosis, starting in distal esophagus. Biopsies reveal neutrophils and eosinophils in epithelial layer, basal cell hyperplasia and elongated papillae. More severe cases have ulceration. Late complications include fibrotic stricture, glandular metaplasia of mucosal epithelium (*Barrett's esophagus*), and increased incidence of carcinoma, particularly adenocarcinoma.

Clinically, GER is diagnosed by history of heartburn symptoms, x-ray to show reflux, endoscopy and biopsy to reveal esophagitis, and manometry to determine cause. Patients with chronic reflux esophagitis and Barrett's esophagus require periodic surveillance with endoscopy and biopsy to detect epithelial dysplasia and early carcinoma.

D. Other miscellaneous conditions

1. **Radiation injury** follows treatment of tumors of the esophagus and the adjacent organs. Early changes include ulceration and marked edema. The late effect of radiation is fibrotic stricture.
2. Drug effects or “**pill esophagitis**” present as focal ulceration, usually due to physical entrapment of pill and pressure necrosis. Hypersensitivity reactions are rare, yielding more diffuse inflammation.
3. Esophageal mucosa may be involved in immune disorders such as graft-versus-host disease following bone marrow transplantation. Allergic (eosinophilic) gastroenteritis may also involve the esophagus.
4. **Mallory-Weiss lacerations** are vertical, linear lacerations at the esophageal-gastric junction, believed to be due to severe retching and vomiting. Lacerations may cause extensive hemorrhage and rarely perforation. They are more common in alcoholics, and bulimic.
5. The esophagus may rarely be affected by conditions primarily of the stratified epithelium of the skin (e.g., pemphigus) or diffuse diseases of the digestive tract (e.g., Crohn's disease).
6. **Glycogenic acanthosis** refers to slightly raised white plaques in mucosa of distal esophagus, due to simple hyperplasia of epithelium. It is commonly seen at endoscopy, but is of no clinical significance.

Selected References

1. Ming SC, Goldman H. Pathology of the Gastrointestinal Tract. Williams & Wilkins., Philadelphia, 1998.
2. Feldman M, Scharschmidt BF, Sleisinger MH, eds. Sleisinger and Fordtran's Gastrointestinal and Liver Disease, 6th ed. WB Saunders, Philadelphia, 1998. Pp.457-539.
3. Cohen S. Motor disorders of the esophagus. *N Engl J Med* 1979; 301:184.
4. Dobbs WJ, Hogan WJ, Helm JF et al. Pathogenesis of reflux esophagitis. *Gastroenterology* 1981; 81:376.
5. Haggitt RC, Tryzelaar J, Ellis FH, et al. Adenocarcinoma complicating columnar epithelium-lined (Barrett's) esophagus. *Am J Clin Pathol* 1978; 70:1.
6. Spechler and Goyal (eds): Barrett's Esophagus: Pathophysiology, Diagnosis and Management. Elsevier, 1985.
7. Berthrong M, Fajardo LF. Radiation injury in surgical pathology. II. Alimentary tract. *Am J Surg Pathol* 1981; 5:153.
8. Chowhan, N. M. 1990. Injurious effects of radiation on the esophagus. *Am J Gastroenterol* 85:115-120.
9. DeNardi, F. G. and R. H. Riddell. 1991. The normal esophagus. *Am J Surg Pathol* 15:296-309.
10. Cohen, S. 1992. The pathogenesis of gastroesophageal reflux disease: A challenge in clinical physiology. *Ann. Intern. Med.* 117:1051-1052.
11. Spechler SJ, Zeroogian JM, Antonioli DA, Wang HH, Goyal RK. Prevalence of metaplasia at the gastroesophageal junction. *Lancet* 1994;344:1533-1536.
12. Spechler SJ. 2002. Clinical practice. Barrett's esophagus. *N Engl J Med* 346:836-842.

Part II: Stomach

I. ANATOMY

The major anatomic landmarks and areas are schematically presented in Figure 3. In the resting state, the stomach is contracted, its mucosa thrown up into numerous folds called *rugae*, analogous to the folds of the esophageal mucosa. In the presence of a food load, the stomach dilates, the mucosal folds smooth out, and gastric capacity increases tremendously.

II. HISTOLOGY AND PHYSIOLOGY

A. Mucosa

The gastric mucosa is broken up into a mosaic of geographic areas, 1 to 5 mm in diameter, by shallow furrows. Each area contains a number of shallow depressions, called the *gastric pits or foveolae*, into which several gastric glands empty their secretions. The gastric *fundic or corpus*-type glands are long, variably branched tubules, each having a base, neck, and isthmus, the latter emptying into a gastric pit. These glands occupy the fundus and corpus of the stomach. Their lining cells are of various types which produce mucin, HCl, intrinsic factor, and pepsinogen. In the *cardiac and pyloric areas*, the glands are simpler, often branched and contain a greater percentage of mucin-producing cells.

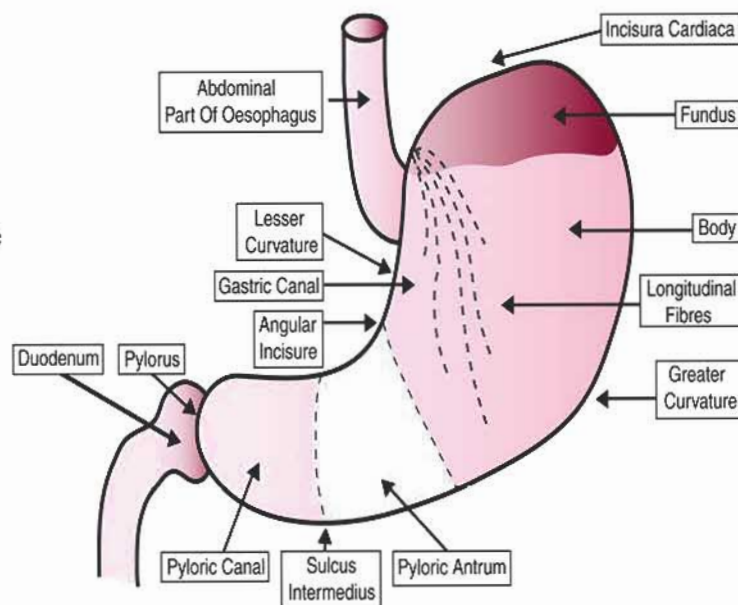


Figure 3. Anatomical landmarks of the stomach

The demarcations between cardiac, fundic/corpus type, and pyloric glands are not sharp, and are characterized by the presence of transitional zones. Studies have shown a proximal progression of pyloric glands in the stomach with increasing age. This change is more marked on the lesser curvature, and is presumably due to metaplasia of fundic glands into the structurally more simple pyloric glands. The reason for this change is unknown.

Gastric epithelium is histologically complex, and contains several major cell types (Table 1, Figure 4):

- a. *Surface-foveolar mucous cells* line foveolae (pits) and gastric surface between foveolae throughout the entire stomach. They are columnar cells with short sparse microvilli on the apical surface, contain small dense apical mucus granules filled with neutral glycoproteins. They secrete mucin and bicarbonate, thus creating a neutral microenvironment above the epithelium, protecting it from the low luminal pH.
- b. *Mucous neck cells* are found singly and in small clusters among the parietal cells and occasionally between chief cells in the gastric glands, and a few may be found in neck area of cardiac and pyloric glands. These cells are columnar or flask-shaped, with short sparse microvilli. Mucous neck cells contain apical and paranuclear mucous granules that are slightly larger and less dense than those of surface-foveolar mucous cells. These granules contain sialomucin (acidic glycoprotein) as well as neutral glycoproteins. Recent studies have shown that some of these cells also contain pepsinogens similar in type to those found in the chief cells. Mucous neck cells are precursor (stem) cells, giving rise to surface-foveolar mucous cells, parietal cells and chief cells. Therefore, the areas where mucous neck cells are located (neck and isthmus of gastric glands) define the areas of normal epithelial cell renewal in the stomach.

c. *Mucous cells of cardiac and pyloric glands* are structurally different from surface-foveolar mucous cells in that the mucous granules are less dense, distributed rather diffusely throughout the cytoplasm, and contain slightly acidic, as well as neutral glycoproteins. Their appearance is very similar to that of Brunner glands in the duodenum. Many of these cells, especially near the gland bases, contain pepsinogens, the functional significance of which is unclear. Very few chief cells are identifiable in these glands. Small numbers of zymogen-like granules, in addition to the numerous mucous granules noted above, are present in these cells. The function of these cells is unclear, but their secretion may assist the Brunner gland and pancreatic secretions in neutralizing gastric acid.

d. *Parietal (oxyntic) cells* are primarily located in the neck and isthmus regions of the gastric glands in the corpus of the stomach. Smaller numbers of parietal cells can be found throughout the antrum, as far as the gastroduodenal junction. Parietal cells are pyramidal, with the narrow apex at gland lumen. They

are deeply eosinophilic by H&E staining, due to very large cytoplasmic component of mitochondria. Their most typical electron microscopic features are complex invagination of free surface membrane to form a *secretory canaliculus* lined with long microvilli; numerous mitochondria; and variable numbers of microtubules and vesicles in cytoplasm. These cells are the *source of HCl* in gastric juice. When parietal cells are stimulated to produce HCl, two morphologic changes occur. First, there is a decrease in tubules and vesicles in the cytoplasm. Second, there is an increased number and length of the microvilli. When stimulated to secrete HCl, the tubulovesicles fuse with the canalicular membrane, thus markedly increasing the surface area of the cell available for HCl production. In fact, the tubulovesicles may contain the proton pump and fusion may thus be a mechanism of inserting the pumps into the canalicular membrane. With removal of the stimulus for acid secretion, the parietal cells reassume their "resting" configuration. Parietal cells are also the source of *intrinsic factor* which is required for vitamin B₁₂ absorption.

e. *Zymogenic (chief) cells* are found primarily in fundic and corpus areas of stomach, near the base of the gastric glands. They are cuboidal to columnar, with short microvilli. The deeply basophilic cytoplasm in H&E preparations is due to large number of ribosomes. These cells have the typical EM appearance of protein-producing cells: basilar concentration of rough endoplasmic reticulum, well-developed supranuclear Golgi complex, and apical concentration of vacuoles containing the finished secretory product. Chief cells produce and release inactive pepsinogen which is converted to active pepsin on contact with luminal hydrochloric acid. Pepsin, which works best at a low pH, begins proteolytic digestion. They also produce gastric lipase, a preduodenal lipase with acidic pH optimum, which is active on dietary triglycerides.

f. *Endocrine cells*. The stomach and duodenum produce polypeptide hormones such as gastrin (chiefly stomach) and secretin (duodenum), as well as various vasoactive and other amines such as 5-hydroxytryptamine (serotonin). Only in the past few years, have cells with hormone- and amine-producing features been identified in the stomach.

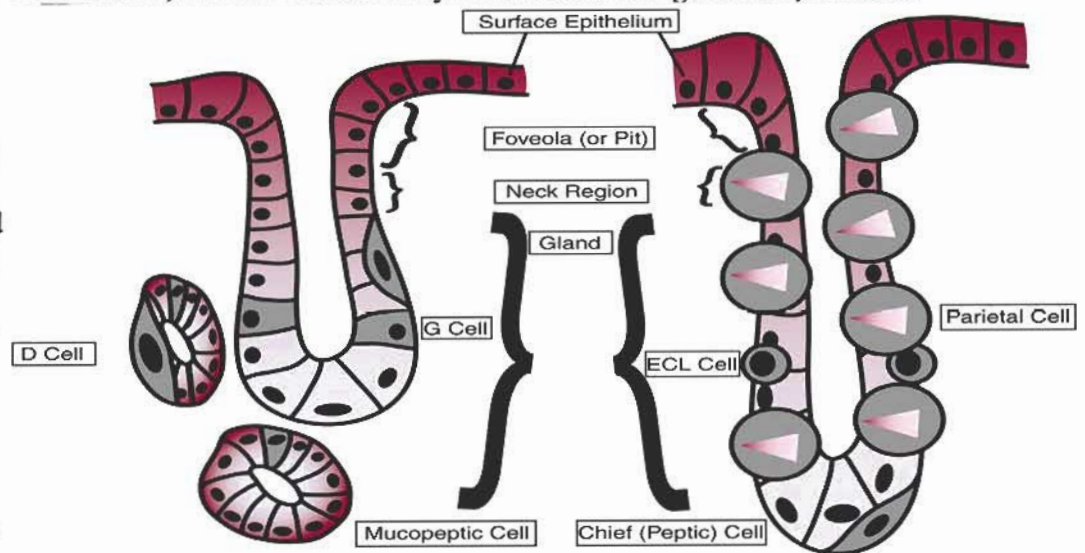


FIGURE 4. Basic mucosal histology of the stomach.

Table 1: Summary of Gastric mucosal cell types, location, and function

Cell Type	Cardia	Fundus	Corpus	Pylorus	Location in the gland	Main function
Foveolar cells	+++	+++	+++	+++	surface/pits	mucin production
Mucous neck cells	++	+++	+++	++	neck/isthmus	regenerative activity
Cardia & pyloric mucous cells	+++	-	-	+++	entire length	mucin production
Parietal cells	-	++	+++	+	neck/isthmus	HCL & IF production
Chief cells	-	+++	+++	+	base	Pepsinogen & lipase production

The characteristic of endocrine cells is the electron microscopic demonstration of *basal and paranuclear secretory granules* which vary in number, size, and density, depending on cell type. The osmiophilic granules in these cells do not stain in light microscopic sections without prior reaction with silver salts using various histochemical techniques; hence, the use of the names *argentaffin* and *argyrophil* for these cells in paraffin-embedded material. Many of these cells do not reach the gland lumens; rather, they lie deep against the basement membrane. The EC and D cells have extensive granulated basal processes along the basal lamina, suggesting release of granular content from this part of the cell.

The best-known endocrine cells are the "G" cells, the "EC" cells, and the "D" cells. The "G" cells are the source of gastrin. The factors influencing the release of gastrin, such as alkaline substances and antral distention, will be discussed in other lectures. The "EC" cells produce 5-hydroxytryptamine, whose role in normal digestion is unknown. The D cells appear to contain somatostatin and have low density granules by EM. Another way these endocrine cells influence function is via *paracrine* effects. For example, D cells have long basal processes which extend throughout the local neighborhood of epithelial cells. Via this structural specialization, D cells exert paracrine effects. The endocrine cells occur throughout the intestine. Recent studies suggest that these cells arise in the neural crest and migrate into the gut to form a diffuse enteric endocrine system.

B. Submucosa: No special features.

C. Muscularis externa

There are 3 layers in the stomach: Inner - oblique, middle - circular, and outer - longitudinal, with two major functions. *Receptive relaxation* for food storage is a reflex response to pharyngeo-esophageal movement in which relaxation occurs chiefly in the fundus and proximal corpus. This distention allows a large food volume to be accommodated without much increase in intragastric pressure. *Antral peristalsis* is responsible for mixing food and delivering it to bowel. Regular rhythmic peristaltic waves begin in corpus, increase in amplitude as they pass distally, and end with a mass contraction of the distal antrum and pylorus (*antral systole*). This systole forces still solid food back into the stomach for further mixing. The net gastric emptying of semiliquid material (chyme) is graded and controlled by as yet undefined mechanisms. Vagal stimulation and gastrin stimulate peristalsis, while sympathetic neural activity inhibits it. At the junction of stomach and duodenum, the muscularis is thickened to form the *pyloric sphincter*. It normally appears to prevent the reflux of duodenal contents into the stomach to any significant degree. Mechanisms of its control are unclear. Some workers feel it is, like the LES, a high pressure zone in the resting state, but there are conflicting reports in the literature.

D. Serosa: Has no special features.

III. GASTRITIS

Gastritis is an inflammatory disorder of the gastric mucosa, which may be focal or diffuse, acute or chronic. Chronic gastritis is often associated with mucosal atrophy.

A. Acute gastritis

Acute gastritis is commonly related to ingestion of salicylates, ethanol and other toxic substances, and bile reflux from duodenum, resulting in damage to the gastric mucosal barrier. Damaged mucosal barrier permits back diffusion of hydrogen ions, tissue acidosis and injury. The early mucosal changes include edema and congestion of lamina propria, followed by destruction of surface and pit epithelium and neutrophilic inflammation. More severe cases show erosions (superficial) or ulcers (deeper), and there may be prominent hemorrhage. Deeper parts of the wall are usually spared. Rarely, there may be loss of specialized glands. Acute gastritis is generally self-limited, with healing after removal of the toxic inciting agent. Healing phase is characterized by regeneration of epithelium and residual inflammation. Clinical presentation is variable. Patients may be asymptomatic, or present with nausea, vomiting, and epigastric pain. Diagnosis is based on history and endoscopic examination. Since lesions are superficial, x-ray studies of the stomach are usually not helpful unless air-contrast study is done.

B. Chronic gastritis

Chronic gastritis encompasses a group of conditions of diverse etiologies and variable histology. Incidence and prevalence are unclear. Lesions are often asymptomatic and found at autopsy or at gastric biopsy or surgery for other conditions. Major known etiologies are listed below.

- a. *Helicobacter pylori*, a spiral bacterium noted along surface of mucous cells in gastric pits, plays a major role in acute and chronic gastritis, particularly in antrum. Evidence favors that *H. pylori* acts not as a primary causal organism, but as one that exacerbates injury once established, and predisposes to chronic gastric inflammation. *H. pylori* may also be related to persistence and recurrence of peptic ulcers.
- b. Some cases of chronic gastritis are related to *multiple episodes of acute gastritis*.
- c. *Reflux* of bile into stomach with mucosal barrier damage can lead to chronic gastritis. This is particularly prominent in cases following antral resection and anastomosis (Billroth I and II operations).
- d. There is an often asymptomatic increase in incidence and severity of chronic gastric inflammation after 50 years of age. Changes are most marked in antrum, then tend to involve corpus in older persons.

General pathological features of chronic gastritis include variable degrees of acute and chronic inflammation in lamina propria; hyperplasia of surface-foveolar mucous cells and endocrine cells; atrophy of specialized parietal and chief cells; and metaplasia (intestinal and pyloric types). Classification of chronic gastritis is primarily based on pathological features.

- i. *Chronic antral gastritis*: There is frequent history of acute gastritis, related to alcohol, drugs, bile reflux or *H. pylori* infection. Lesion is limited to antrum, showing inflammation, hyperplasia and metaplasia of surface foveolar cells. Pyloric glands may be increased or decreased, and there may be a reduction in antral endocrine cells.
- ii. *Chronic atrophic gastritis*: Is much more common in older persons, with an insidious onset and a probable link to immune dysfunction. Lesions may start in fundus-corpora but often involve the antrum as well in later stages. Features include inflammation, loss of parietal and chief cells, hyperplasia and metaplasia of surface-foveolar mucous cells, and increase in antral gastrin cells due to loss of acid production and loss of feedback control of gastrin release.
- iii. *Severe atrophic gastritis (gastric atrophy)*: Is the form of chronic gastritis most likely to be symptomatic. Loss of parietal cells followed by intestinal metaplasia means loss of intrinsic factor and vitamin B₁₂, malabsorption followed by megaloblastic anemia (*pernicious anemia*). The concurrent loss of HCl

production has no definite clinical effect, but seems to predispose to an increased risk of developing enteric infections. Antibodies against parietal cells and against intrinsic factor are common in serum and gastric juice of patients with atrophic gastritis. These are also found in relatives of pernicious anemia patients, who have some degree of gastritis on biopsy, show variable degrees of acid secretion, but usually have no anemia. The antibodies probably develop in response to antigenic material released by the as yet undefined initial mucosal injury. However, once present, the antibodies may serve to propagate the disease state. It is felt that the gastric atrophy-intestinal metaplasia-pernicious anemia complex represents a premalignant condition, with an increased incidence of gastric carcinoma in long-term follow-up of these patients.

- iv. *Post-gastrectomy chronic gastritis*: Is common following antral resection and gastroduodenal (Billroth I) or gastro-jejunal (Billroth II) anastomosis, due to free bile reflux into the stomach. Lesions are more prominent close to the site of anastomosis. Pathologic features are similar to chronic atrophic gastritis, with an increased occurrence of polyps and, perhaps, of adenocarcinoma in gastric remnant.

C. Other uncommon forms of gastritis

1. *Granulomatous gastritis*: Tuberculosis; sarcoidosis; Crohn's disease; idiopathic (isolated). Major changes tend to be seen in the antrum. Often the presentation is that of antral-pyloric stenosis with obstruction secondary to fibrosis of gastric wall, mimicking tumor.
2. *Eosinophilic gastritis*: Diffuse or localized infiltration of eosinophils in gastric wall, particularly in the antrum. May be confined to stomach or be part of a diffuse eosinophilic gastroenteritis characterized by epithelial necrosis, protein-losing enteropathy, iron-deficiency anemia (secondary to GI blood loss), and peripheral eosinophilia.
3. *Infections*: Low incidence compared to other parts of the digestive tract, perhaps related to high luminal acidity. The most common types of gastric infection are:
 - a. Secondary bacterial infection in burn/trauma patients.
 - b. Opportunistic infections - cytomegalovirus, fungi, atypical mycobacteria.
 - c. Secondary monilial infections in peptic ulcers, potentially enhanced by modern antacid therapy with H₂-blocking agents.
 - d. *H. pylori*: See above.

IV. HYPERTROPHY OF GASTRIC MUCOSA (HYPERTROPHIC GASTROPATHY)

This is another diverse group of entities which grossly present as thickened irregular gastric mucosa either in the corpus and fundus or throughout the stomach. Mucosal hypertrophy may be classified based on the components involved.

1. *Hypertrophy of rugae*: Congenitally large rugae, mucosal histology normal, redundant submucosa, no clinical significance
2. *Hypertrophy due to hyperplasia of parietal cells (Zollinger-Ellison syndrome)*: Parietal cell hyperplasia due to gastrin-producing tumor of pancreatic islets (about 90% of cases), of proximal duodenum (7%), or to antral G-cell hyperplasia (3%). Tumors are often malignant but slow growing. Excess gastrin results in maximal stimulation of gastric parietal cells, leading to excessive gastric acid, multiple ulcers of stomach and duodenum, and malabsorption in some cases (related to dilution, inactivation of lipases, and bile salt precipitation).
3. *Hypertrophy due to hyperplasia of surface-foveolar mucous cells (Menetrier's disease)*: Elongated gastric pits, often with cystic dilatation of the glands at their base. There may be a relative decrease in parietal cells secondary to the increased number of surface-foveolar cells, which extend variable distances down the gland.

Usually confined to corpus of stomach. There may be variable inflammation in lamina propria. Foveolar hyperplasia leads to overproduction and secretion of mucus which in turn may lead to a protein-losing enteropathy. Hypochlorhydria is common. Cause is unknown in adults, but often follows viral gastroenteritis in children. In adults takes a chronic course, with, perhaps, an increased long-term incidence of gastric carcinoma. In children, it is a self-limited disease.

4. *Rugal hypertrophy secondary to infiltration* of the gastric submucosa and mucosa by a malignant process, especially by gastric carcinoma or lymphoma.

V. ACUTE STRESS ULCER

Discrete ulcers of upper gastrointestinal tract are seen after various severe stress situations, such as central nervous system damage (Cushing's ulcer), extensive burns (Curling's ulcer), traumatic injuries, etc. Incidence of acute stress ulcers complicating the patient's basic clinical problem varies from 0.5 to 11.0% in different series. Most ulcers develop 6-14 days after the acute injury. Incidence may be decreased by monitoring gastric pH and by prophylactic use of antacids and drugs which block H₂ receptors on parietal cells.

Pathology varies from superficial mucosal erosions with minimal inflammatory reaction, to deep mural ulcers, or transmural ulcers with perforation. Lesions are commonly multiple, and more common in stomach than duodenum (a reversal of the situation in chronic peptic ulcer disease).

Pathogenesis is unclear in most cases, but multiple factors probably involved. In some CNS lesions, there is a vagal stimulation, resulting in increased gastric acid secretion. However, in other situations where stress ulcers develop, there is no good evidence of hyperacidity. Mucosal ischemia secondary to blood stasis locally (? mediated via histamine or increased intragastric pressure) and changes in splanchnic blood flow, may also play a role. Ischemia may make mucosa more susceptible to acid-pepsin effects. Finally, drugs such as corticosteroids are commonly used in critically ill patients, and may damage the gastric mucosal barrier.

Stress ulceration is characterized by pain and hemorrhage, the latter sometimes massive. If medical therapy is ineffective, subtotal gastrectomy may be performed. Most patients survive and ulcers heal.

VI. CHRONIC PEPTIC ULCER DISEASE (PUD)

PUD presents as chronic and recurrent discrete ulcers of the gastric and duodenal mucosa due to action of gastric acid and pepsin. Ulcers are most often found in the duodenum (80%), and less commonly the distal stomach (20%). Other less common sites include the lower esophagus (secondary to reflux), and adjacent to sites of ectopic gastric mucosa such as in Meckel's diverticula.

Grossly, ulcers tend to be single, deep, with sharp, well-defined margins. Mucosal folds extend to margin of ulcer. *This appearance is different from ulcerating carcinomas with irregular contour, and overhanging margins.* With healing, there is distortion of mucosal folds, and variable fibrosis. Microscopically, the ulcer base contains fibrin, inflammation, and necrotic debris. Underneath is granulation tissue, and deepest of all (usually in muscularis propria) is fibrosis. With healing, granulation tissue and fibrosis fill the defect, and mucosa regenerates. Complications occur in up to 20% of cases, and include:

- a. Non-healing of ulcer or recurrent ulceration.
- b. Hemorrhage: amount varies, depending on size of vessels eroded by ulcer process.
- c. Perforation: destruction of entire wall. Symptoms will depend on area in which perforation occurs: evidence of peritonitis, pancreatitis, etc.
- d. Obstruction: usually related to ulcers in pyloric-peripyloric areas. Obstruction is either due to edema and spasm associated with active ulcers (reversible with healing of the ulcer), or due to fibrosis associated with chronicity (irreversible).

VII. MISCELLANEOUS CONDITIONS

A. Motor disorders include gastric atony and dilatation with severe distention of stomach may be seen in some patients with neurologic diseases and post-operatively. It is more common in diabetes mellitus, and may result in secondary mucosal necrosis. Stomach may also be involved in various muscle diseases such as systemic sclerosis and visceral myopathy, but functional-clinical effects are rare.

B. Vascular disorders include varices in patients with portal hypertension (see notes on esophagus), and rarely, vascular malformations, and vasculitis.

C. Tumor-like inflammatory lesions

1. *Xanthomas (xanthelasmas)* are discrete, small yellow patches in mucosa, due to localized accumulation of lipid-rich macrophages. They may be a sequelae of mucosal hemorrhage of any cause. It is seen often at endoscopy, but is of no clinical importance.
2. *Gastritis cystica* is a florid example of chronic gastritis, often associated with variable degree of polyp formation and extension of mature glands into submucosa. Gastritis cystica must be distinguished from invasive carcinoma.
3. *Pseudolymphoma* is an inflammatory mass that may mimic malignant lymphoma. It may require resection for definitive diagnosis.

Selected References

1. Loffeld, B. C. A. J. and J. P. Van Spreuwel. 1991. The gastrointestinal tract in pernicious anemia. *Dig. Dis. Sci.* 9:70-77.
2. Komorowski, R. A. and J. G. Caya. 1991. Hyperplastic gastropathy: Clinicopathologic correlation. *Am. J. Surg. Pathol.* 15:577-585.
3. Rugge, M., F. Di Mario, M. Cassaro, R. Baffa, F. Farinati, J. Rubio, Jr., and V. Ninfo. 1993. Pathology of the gastric antrum and body associated with *Helicobacter pylori* infection in non-ulcerous patients. *Histopathology* 22:9-15.
4. Wolfsen, H. C., H. A. Carpenter, and N. J. Talley. 1993. Menetrier's disease: A form of hypertrophic gastropathy or gastritis. *Gastroenterology* 104:1310-1319.
5. Lamberts, R., W. Creutzfeldt, H. G. Strüber, G. Brunner, and E. Solcia. 1993. Long-term omeprazole therapy in peptic ulcer disease: Gastrin, endocrine cell growth, and gastritis. *Gastroenterology* 104:1356-1370.
6. Hills, B. A. 1993. Gastric mucosal barrier: Evidence for *Helicobacter pylori* ingesting gastric surfactant and deriving protection from it. *Gut* 34:588-593.
7. Hui, P. K., W. Y. Chan, P. S. Cheung, J. K. C. Chan, and C. S. Ng. 1992. Pathologic changes of gastric mucosa colonized by *Helicobacter pylori*. *Hum. Pathol.* 23:548-556.
8. Parsonnet J, Hansen S, Rodriguez L, Gelb AB, Warnke RA, Jellum E, Orentreich N, Vogelmann JH, Friedman GD. *Helicobacter pylori* infection and gastric lymphoma. *N Engl J Med* 1994;330:1267-1271.
9. Wyatt JI. Histopathology of gastroduodenal inflammation: The impact of *Helicobacter pylori*. *Histopathology* 1995;26:1-15.
10. Carpenter HA, Talley NJ. Gastroscopy is incomplete without biopsy: Clinical relevance of distinguishing gastropathy from gastritis. *Gastroenterology* 1995;108:917-924.