

MIT Open Access Articles

*CHOROIDAL THICKNESS IN PATIENTS WITH
DIABETIC RETINOPATHY ANALYZED BY SPECTRAL-
DOMAIN OPTICAL COHERENCE TOMOGRAPHY*

The MIT Faculty has made this article openly available. **Please share** how this access benefits you. Your story matters.

Citation: Regatieri, Caio V., Lauren Branchini, Jill Carmody, James G. Fujimoto, and Jay S. Duker. "CHOROIDAL THICKNESS IN PATIENTS WITH DIABETIC RETINOPATHY ANALYZED BY SPECTRAL-DOMAIN OPTICAL COHERENCE TOMOGRAPHY." *Retina* (February 2012): 1.

As Published: <http://dx.doi.org/10.1097/iae.0b013e31822f5678>

Publisher: Ovid Technologies (Wolters Kluwer) - Lippincott Williams & Wilkins

Persistent URL: <http://hdl.handle.net/1721.1/86410>

Version: Author's final manuscript: final author's manuscript post peer review, without publisher's formatting or copy editing

Terms of use: Creative Commons Attribution-Noncommercial-Share Alike





Published in final edited form as:

Retina. 2012 March ; 32(3): 563–568. doi:10.1097/IAE.0b013e31822f5678.

CHOROIDAL THICKNESS IN PATIENTS WITH DIABETIC RETINOPATHY ANALYZED BY SPECTRAL-DOMAIN OPTICAL COHERENCE TOMOGRAPHY

CAIO V. REGATIERI, MD, PhD^{*,†}, LAUREN BRANCHINI, BA^{*,‡}, JILL CARMODY, MD^{*}, JAMES G. FUJIMOTO, PHD[§], and JAY S. DUKER, MD^{*}

^{*}New England Eye Center, Tufts Medical Center, Boston, Massachusetts

[†]Department of Ophthalmology, Federal University of São Paulo, São Paulo, Brazil

[‡]Department of Ophthalmology, Boston University School of Medicine, Boston, Massachusetts

[§]Department of Electrical Engineering and Computer Science, Research Laboratory of Electronics, Massachusetts Institute of Technology, Cambridge, Massachusetts

Abstract

Purpose—This study was designed to examine choroidal thickness in patients with diabetes using spectral-domain optical coherence tomography.

Methods—Forty-nine patients (49 eyes) with diabetes and 24 age-matched normal subjects underwent high-definition raster scanning using spectral-domain optical coherence tomography with frame enhancement software. Patients with diabetes were classified into 3 groups: 11 patients with mild or moderate nonproliferative diabetic retinopathy and no macular edema, 18 patients with nonproliferative diabetic retinopathy and diabetic macular edema, and 20 patients with treated proliferative diabetic retinopathy and no diabetic macular edema (treated proliferative diabetic retinopathy). Choroidal thickness was measured from the posterior edge of the retinal pigment epithelium to the choroid/sclera junction at 500- μm intervals up to 2,500 μm temporal and nasal to the fovea.

Results—Reliable measurements of choroidal thickness were obtainable in 75.3% of eyes examined. Mean choroidal thickness showed a pattern of thinnest choroid nasally, thickening in the subfoveal region, and thinning again temporally in normal subjects and patients with diabetes. Mean subfoveal choroidal thickness was thinner in patients with diabetic macular edema (63.3 μm , 27.2%, $P < 0.05$) or treated proliferative diabetic retinopathy (69.6 μm , 30.0%, $P < 0.01$), compared with normal subjects. There was no difference between nonproliferative diabetic retinopathy and normal subjects.

Conclusion—Choroidal thickness is altered in diabetes and may be related to the severity of retinopathy. Presence of diabetic macular edema is associated with a significant decrease in the choroidal thickness.

Keywords

choroid; choroidal angiopathy; diabetes mellitus; diabetic retinopathy; optical coherence tomography

Diabetic retinopathy is a leading cause of vision loss worldwide.¹ The development of macular edema and proliferative retinopathy are major causes of visual impairment.^{1,2} Clinical and experimental findings suggested that choroidal vasculopathy in diabetes may play a role in the pathogenesis of diabetic retinopathy.³⁻⁵

Various choroidal abnormalities including obstruction of the choriocapillaris, vascular degeneration, choroidal aneurysms, and choroidal neovascularization have been reported in histopathologic studies of diabetic eyes.^{3,6,7} In addition, McLeod and Luttý⁸ observed a loss of alkaline phosphatase activity in the diabetic choriocapillaris that represents loss of viable endothelial cells and concurrent degeneration of the choriocapillaris.

There are few clinical studies on choroidal angiopathy in diabetes. This is because of the difficulty of imaging the choroid in vivo. Indocyanine green angiography reveals both hyper- and hypofluorescent spots in diabetic eyes, although the significance is unknown.^{4,9} It has been proposed that the hypofluorescent spots result from ischemic changes of the choroidal vessels and represent either a dye filling delay or a defect of the choriocapillaris.^{7,10} It is further postulated that the hyperfluorescent spots may be secondary to the presence of choroidal neovascularization, intra-choroidal microvasculature abnormalities, or nodules at the level of the choriocapillaris or underlying stroma.^{4-6,9} Concurrently, Shiragami et al⁵ described risk factors associated with diabetic choroidopathy including the presence of severe diabetic retinopathy, poor glycemic control, and the nature of the treatment regimen.

Additionally, studies assessing the choroidal blood flow beneath the fovea with the use of laser Doppler flowmetry indicate a reduction of choroidal blood flow and volume in patients with nonproliferative¹¹ and proliferative diabetic retinopathy. There was a more prominent decrease in flow in the case of proliferative diabetic retinopathy.¹²

A better clinical understanding of choroidal damage might be important for an accurate assessment of diabetic eye disease, but adequate visualization of the choroid using optical coherence tomography (OCT) has not been possible until recently, owing to its posterior location and the presence of pigmented cells that attenuate the incident light. Recent reports showed successful examination and measurement of choroidal thickness in normal and pathologic states using the Heidelberg Spectralis (Heidelberg Engineering, Heidelberg, Germany) and Cirrus HD-OCT (Carl Zeiss Meditec Inc, Dublin, CA) spectral-domain OCT instruments.¹³⁻¹⁷ The present study was designed to determine if CT is abnormal in patients with various stages of diabetic retinopathy.

Methods

Subjects

A retrospective analysis was performed on 49 eyes of 49 Type 2 diabetic patients and 24 eyes of 24 normal patients, who underwent high-definition 1-line raster scanning using SD Cirrus HD-OCT at the New England Eye Center, Tufts Medical Center, Boston, MA, between December 2009 and June 2010. The normal subjects had normal visual acuity and did not have any retinal or choroidal pathology on ophthalmoscopy.

The patients with diabetes were classified into 3 groups, according to the Early Treatment Diabetic Retinopathy Study criteria: 11 patients (11 eyes) with mild or moderate nonproliferative diabetic retinopathy (NPDR) and no macular edema (NPDR group), 18 patients (18 eyes) with mild or moderate NPDR and diabetic macular edema (DME) (DME group), and 20 patients (20 eyes) with treated proliferative diabetic retinopathy (PDR) (treated PDR group). Clinically significant macular edema was assessed by clinical

examination and spectral-domain OCT imaging, and it was diagnosed based on the presence or absence of macular thickening or hard exudates at or within 500 μm of the central macula, as defined by the Early Treatment Diabetic Retinopathy Study protocol.^{18,19} All patients with PDR were treated previously with panretinal photocoagulation and did not demonstrate active retinal neovascularization. Major exclusion criteria included the following: (1) another ocular diseases (2) previous treatment for DME within 6 months of scanning, and (3) previous pars plana vitrectomy. Patients were excluded if the hypertension was uncontrolled or if they had a history of pancreatic transplant or chronic renal failure requiring dialysis or kidney transplant.

Choroidal Thickness Measurement

The scan pattern used on Cirrus HD-OCT was HD 1-line raster. It is a 6-mm line consisting of 4,096 A-scans. Images were taken with the vitreoretinal interface adjacent to the zero-delay and were not inverted to bring the choroid adjacent to zero-delay as image inversion using the Cirrus software results in a low-quality image. The HD 1-line raster has 20 B-scans averaged together without tracking. To be included in this study, images had to be at least 6 of 10 in intensity and taken as close to the fovea as possible, by choosing to image the thinnest point of the macula, with the understanding that slight differences in positioning could affect the measured thicknesses. Using the Cirrus linear measurement tool, 2 independent observers measured CT perpendicularly from the outer edge of the hyperreflective retinal pigment epithelium (RPE) to the inner sclera at 500- μm intervals temporal and nasal from the fovea, up to 2,500 μm . Furthermore, the central foveal thickness was also measured at this time to determine the correlation between retinal thickness and CT.

Statistical Analysis

Data are expressed as means \pm standard error of the mean. Statistical analyses were performed using one-way analysis of variance followed by posttest comparison with Tukey multiple test. Pearson correlation coefficient was used to evaluate the correlation between the CTs and central foveal thickness. A 95% confidence interval and a 5% level of significance were adopted; therefore, the results with a P value ≤ 0.05 were considered significant. All statistics were calculated using Graph Pad Prism 5.0 software for Windows.

Results

Table 1 shows the characteristics of diabetic patients and normal subjects. No significant difference in age was observed between the 4 groups ($P = 0.958$). The patient percentage in use of insulin was higher in treated PDR group, compared with NPDR and DME.

Reliable measurements of CT were obtainable in 75.3% of the diabetic patients (49 of 65 patients). Mean CT at each location was plotted (Figure 1). There was a statistically significant difference between CT of normal subjects and DME group ($P < 0.001$) and treated PDR group ($P < 0.001$). No significant difference between normal subjects and the NPDR group was observed ($P > 0.05$). Between DME and treated PDR groups, there was no significant difference ($P > 0.05$). Representative images are shown in Figure 2.

Table 2 shows the average CT in each location. The choroid was noted to be thinnest nasally, thicker in the subfoveal region, and then thinner again temporally (however, not as thin as the choroid proximal to the disk). This pattern was observed in all groups, and it was in agreement with previous studies of CT in normal eyes.^{13,17,20,21}

The subfoveal CT was noted to be thinner in patients with diabetic macular edema (63.3 μm , 27.2%, $P < 0.05$) or treated PDR (69.6 μm , 30.0%, $P < 0.01$), compared with normal

subjects (Figure 3). No significant difference between normal and NPDR group was observed ($10.3 \mu\text{m}$, 4.5%, $P > 0.05$).

The correlation between central foveal thickness of the retina and central foveal CT was also examined. No statistically correlation between 2 measurements was found in NPDR group ($r = 0.016$, $P = 0.36$) and treated PDR group ($r = -0.176$, $P = 0.25$), suggesting that retinal thickness may not be directly related to CT in these groups. In DME patients, a weak negative correlation was observed ($r = -0.4061$, $P = 0.12$) indicating that the central retinal thickness increases as the CT decreases.

Discussion

A structurally and functionally normal choroidal vasculature is essential for function of the retina: abnormal choroidal blood volume and/or compromised flow can result in photoreceptor dysfunction and death.⁶ The possible role of choroidal vessels in the pathophysiology of diabetic changes in the retina has been evaluated by histologic examination. The pathologic findings included increased tortuosity of the blood vessels, focal vascular dilatation and narrowing, hypercellularity, vascular loops and microaneurysm formation, areas of nonperfusion, and sinuslike structure formation between the choroidal lobules.^{3,22}

Until recently, information regarding CT was based primarily on histologic examinations, which do not necessarily reflect the measurements of this dynamic tissue *in vivo*.²³ Recent studies demonstrate the potential to image choroidal structure using commercially available spectral-domain OCT instruments, the Heidelberg Spectralis and Cirrus HD-OCT.^{15,17} In this investigation, SD Cirrus HD-OCT was used with light source centered on 800-nm wavelength, achieving $5\text{-}\mu\text{m}$ axial resolution in tissue. Previously, the full thickness of the choroid could not be seen in most eyes because of scattering and insufficient light penetration beyond the retinal pigment epithelium, and signal strength roll-off distal to the zero-delay line. Decreased signal strength posterior to the retinal pigment epithelium is compensated by the image enhancement software, which enables visualization of the border where choroidal tissue meets sclera and allows CT measurements to be performed. With the enhanced images, reliable measurements of CT were obtainable in 75.3%. The results of this study were very similar to those reported previously.^{17,20} When considering in which patients it was difficult to visualize the choroid/sclera junction, the most frequent group where this was the case was patients with DME, because of attenuation of the incident light beam by the intraretinal fluid.

Further, previous investigations reported selective filling of the choriocapillaris during indocyanine green angiography and choroidal blood flow decrease during laser Doppler flowmetry in association with non-proliferative diabetic retinopathy. Such findings indicate that there may be diabetic choroidopathy before the onset of diabetic retinopathy in a subset of patients.^{4,11} In our study, significant thinning of the subfoveal choroid was not observed when comparing patients with NPDR and age-matched normals. One explanation for this incongruity is that the above-mentioned findings may be focal and involve mainly the choriocapillaris. Because of resolution limitations of the OCT system used, the choriocapillaris cannot be reliably identified. Further development of OCT technology would likely prove valuable in the investigation of diabetic choroidopathy.

The present study showed a significant decrease in CT in patients with DME and treated PDR, compared with normal subjects. We can speculate that the thinner choroid may indicate an overall reduction of choroidal blood flow in patients with DME and more prominent in patients with treated PDR, as was previously demonstrated with laser Doppler

flowmetry and indocyanine green angiography.^{5,11,12} Therefore, it is likely that the decreased CT may be related to retinal tissue hypoxia, as the choroid is the major source of nutrition for the RPE and outer retinal layers. What is not clear is whether the thinning detected is primary or secondary to overlying retinal ischemia.

Untreated systemic hypertension is associated with choroidopathy, which occurs later than the retinal vascular changes of arteriolar narrowing and arterio-venous crossing changes.²⁴ Although some patients enrolled in this study presented systemic hypertension, it should not interfere in CT because the hypertension was controlled.

This retrospective study has some limitations. Patients with diabetes and no diabetic retinopathy were not included because these patients do not require OCT examination. Additionally, patients with untreated PDR were not included. It is possible that the laser therapy could thin the choroid. Further investigation could examine patients with diabetic retinopathy and compare with CT measured by spectral-domain OCT to correlate the choroidal blood flow and CT.

In conclusion, diabetic choroidal angiopathy is related to the degree of severity of retinopathy and presence of macular edema because of a significant decrease in the CT in patients with diabetic macular edema or treated PDR. Spectral-domain OCT is a noninvasive technology to assess the choroid and may be a useful tool in the evaluation of chorioretinal vascular changes in diabetic retinopathy.

Acknowledgments

Supported in part by a Research to Prevent Blindness Challenge grant to the New England Eye Center/Department of Ophthalmology, Tufts University School of Medicine; National Institutes of Health contracts RO1-EY11289-23, RO1-EY13178-07, and RO1-EY013516-07; and Air Force Office of Scientific Research grants FA9550-07-1-0101 and FA9550-07-1-0014.

J. G. Fujimoto receives royalties from intellectual property owned by M.I.T. and licensed to Carl Zeiss Meditech, Inc, and has stock options in Optovue, Inc. J. S. Duker receives research support from Carl Zeiss Meditech, Inc, Optovue, Inc, and Topcon Medical Systems, Inc.

References

1. Moss SE, Klein R, Klein BE. The 14-year incidence of visual loss in a diabetic population. *Ophthalmology*. 1998; 105:998–1003. [PubMed: 9627648]
2. Klein R, Klein BE, Moss SE, Cruickshanks KJ. The Wisconsin Epidemiologic Study of diabetic retinopathy. XIV. Ten-year incidence and progression of diabetic retinopathy. *Arch Ophthalmol*. 1994; 112:1217–1228. [PubMed: 7619101]
3. Hidayat AA, Fine BS. Diabetic choroidopathy. Light and electron microscopic observations of seven cases. *Ophthalmology*. 1985; 92:512–522. [PubMed: 2582331]
4. Weinberger D, Kramer M, Priel E, et al. Indocyanine green angiographic findings in nonproliferative diabetic retinopathy. *Am J Ophthalmol*. 1998; 126:238–247. [PubMed: 9727518]
5. Shiragami C, Shiraga F, Matsuo T, et al. Risk factors for diabetic choroidopathy in patients with diabetic retinopathy. *Graefes Arch Clin Exp Ophthalmol*. 2002; 240:436–442. [PubMed: 12107509]
6. Cao J, McLeod S, Merges CA, Luttly GA. Choriocapillaris degeneration and related pathologic changes in human diabetic eyes. *Arch Ophthalmol*. 1998; 116:589–597. [PubMed: 9596494]
7. Fukushima I, McLeod DS, Luttly GA. Intrachoroidal microvascular abnormality: a previously unrecognized form of choroidal neovascularization. *Am J Ophthalmol*. 1997; 124:473–487. [PubMed: 9323938]
8. McLeod DS, Luttly GA. High-resolution histologic analysis of the human choroidal vasculature. *Invest Ophthalmol Vis Sci*. 1994; 35:3799–3811. [PubMed: 7928177]

9. Bartsch DU, Weinreb RN, Zinser G, Freeman WR. Confocal scanning infrared laser ophthalmoscopy for indocyanine green angiography. *Am J Ophthalmol.* 1995; 120:642–651. [PubMed: 7485366]
10. Shiraki K, Moriwaki M, Kohno T, et al. Age-related scattered hypofluorescent spots on late-phase indocyanine green angiograms. *Int Ophthalmol.* 1999; 23:105–109. [PubMed: 11196117]
11. Nagaoka T, Kitaya N, Sugawara R, et al. Alteration of choroidal circulation in the foveal region in patients with type 2 diabetes. *Br J Ophthalmol.* 2004; 88:1060–1063. [PubMed: 15258025]
12. Schocket LS, Brucker AJ, Niknam RM, et al. Foveolar choroidal hemodynamics in proliferative diabetic retinopathy. *Int Ophthalmol.* 2004; 25:89–94. [PubMed: 15290887]
13. Margolis R, Spaide RF. A pilot study of enhanced depth imaging optical coherence tomography of the choroid in normal eyes. *Am J Ophthalmol.* 2009; 147:811–815. [PubMed: 19232559]
14. Fujiwara T, Imamura Y, Margolis R, et al. Enhanced depth imaging optical coherence tomography of the choroid in highly myopic eyes. *Am J Ophthalmol.* 2009; 148:445–450. [PubMed: 19541286]
15. Imamura Y, Fujiwara T, Margolis R, Spaide RF. Enhanced depth imaging optical coherence tomography of the choroid in central serous chorioretinopathy. *Retina.* 2009; 29:1469–1473. [PubMed: 19898183]
16. Spaide RF. Age-related choroidal atrophy. *Am J Ophthalmol.* 2009; 147:801–810. [PubMed: 19232561]
17. Manjunath V, Taha M, Fujimoto JG, Duker JS. Choroidal thickness in normal eyes measured using Cirrus HD optical coherence tomography. *Am J Ophthalmol.* 2010; 150:325–329. e321. [PubMed: 20591395]
18. Hee MR, Puliafito CA, Duker JS, et al. Topography of diabetic macular edema with optical coherence tomography. *Ophthalmology.* 1998; 105:360–370. [PubMed: 9479300]
19. Early Treatment Diabetic Retinopathy Study design and baseline patient characteristics. ETDRS report number 7. *Ophthalmology.* 1991; 98:741–756. [PubMed: 2062510]
20. Spaide RF, Koizumi H, Pozzoni MC. Enhanced depth imaging spectral-domain optical coherence tomography. *Am J Ophthalmol.* 2008; 146:496–500. [PubMed: 18639219]
21. Ikuno Y, Kawaguchi K, Nouchi T, Yasuno Y. Choroidal thickness in healthy Japanese subjects. *Invest Ophthalmol Vis Sci.* 2010; 51:2173–2176. [PubMed: 19892874]
22. Fryczkowski AW, Sato SE, Hodes BL. Changes in the diabetic choroidal vasculature: scanning electron microscopy findings. *Ann Ophthalmol.* 1988; 20:299–305. [PubMed: 3190107]
23. Chen TC, Cense B, Miller JW, et al. Histologic correlation of in vivo optical coherence tomography images of the human retina. *Am J Ophthalmol.* 2006; 141:1165–1168. [PubMed: 16765704]
24. Bourke K, Patel MR, Prisant LM, Marcus DM. Hypertensive choroidopathy. *J Clin Hypertens (Greenwich).* 2004; 6:471–472. [PubMed: 15308890]

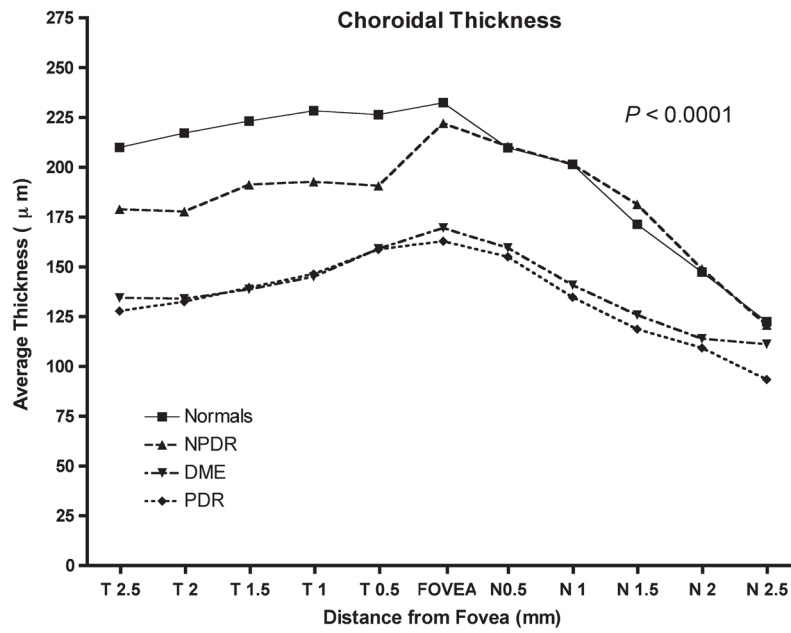


Fig. 1. Graph of mean CT in normal subjects and diabetic patients. Mean CT at each of the 11 locations measured at 500- μm (0.5 mm) intervals temporal (T) and nasal (N). *P* value represents the result of statistical analyses (analysis of variance).

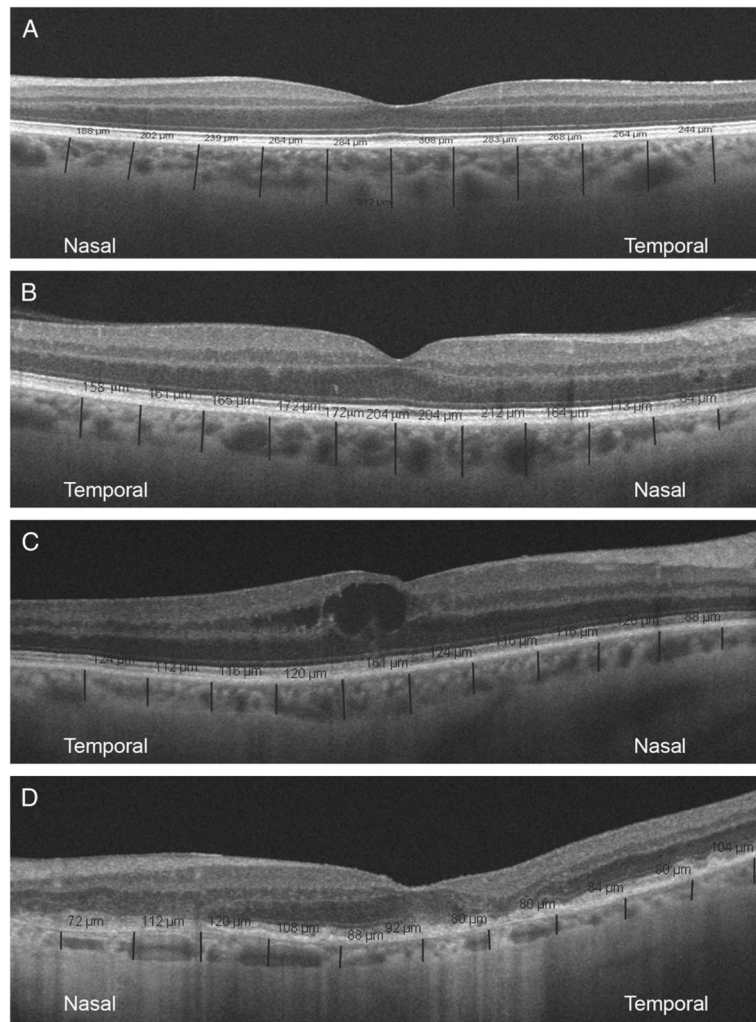


Fig. 2. Representative scans with CT measurements on Cirrus HD-OCT high-definition 1-line raster scans. Perpendicular lines were drawn from posterior edge of RPE to choroid/sclera junction using Cirrus HD-OCT software. Choroidal thickness was measured in the fovea and at 500- μm intervals nasal and temporal to the fovea with the measurements expressed as micrometers (red lines). Note that the choroid is thickest at center, thinner temporally, and thinnest nasally. **A.** Representative scan from a normal subject; **(B)** representative scan from a patient with mild non-proliferative diabetic retinopathy; **(C)** representative scan from a patient with moderate nonproliferative diabetic retinopathy and diabetic macular edema; **(D)** representative scan from a patient with treated proliferative diabetic retinopathy, note that there is a disruption in the photoreceptor inner/outer segment junction probably because of the retinal ischemia.

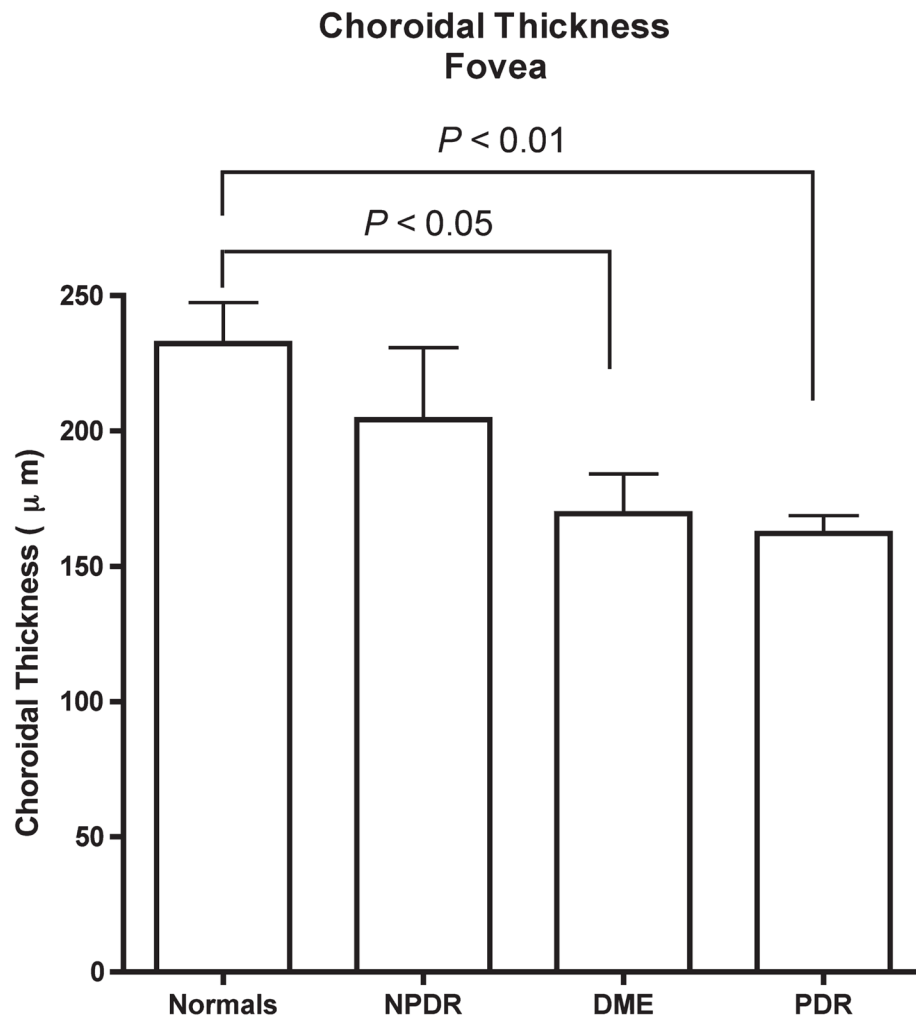


Fig. 3. Graph of mean subfoveal CT in normal subjects and diabetic patients. *P* values represent the results of posttest comparison with Tukey multiple test.

Table 1

Characteristics of Normal Subjects and Diabetic Patients

	Normal	NPDR	DME	PDR
Number (male/female)	24 (14/10)	11 (5/6)	18 (10/8)	20 (12/8)
Age	62 (11.7)	68.5 (9.6)	70.1 (10.7)	62 (9.8)
Use of insulin	NA	3 (27%)	8 (44%)	11 (55%)
Arterial hypertension	NA	8 (72%)	15 (83%)	16 (80%)

NA, not applicable.

Table 2
Mean Choroidal Thickness at Each of the 11 Locations in Normal Subjects and Diabetic Patients

Location (mm From Fovea)	Mean CT (μm)					P
	Normal	NPDR	DME	PDR		
Temporal (2.5)	209.9 \pm 10.5	178.9 \pm 16.4	134.2 \pm 10.1	127.7 \pm 6.5	<0.0001	
Temporal (2.0)	217.2 \pm 10.0	177.7 \pm 16.8	133.8 \pm 10.5	132.4 \pm 6.5	<0.0001	
Temporal (1.5)	223.1 \pm 10.4	191.1 \pm 17.2	138.6 \pm 12.3	139.5 \pm 7.6	<0.0001	
Temporal (1.0)	228.3 \pm 11.4	192.7 \pm 15.3	145.0 \pm 12.1	146.3 \pm 7.3	<0.0001	
Temporal (0.5)	226.3 \pm 13.7	190.6 \pm 12.7	159.0 \pm 14.1	158.7 \pm 9.1	0.0003	
Fovea (0)	232.3 \pm 15.2	222.0 \pm 21.6	169.5 \pm 14.7	162.7 \pm 7.0	0.0027	
Nasal (0.5)	209.7 \pm 13.6	210.4 \pm 19.7	159.4 \pm 12.8	155.0 \pm 6.5	0.0020	
Nasal (1.0)	201.3 \pm 13.6	201.3 \pm 21.7	140.7 \pm 10.6	134.7 \pm 6.5	0.0001	
Nasal (1.5)	171.3 \pm 11.7	181.3 \pm 23.0	125.7 \pm 8.9	118.6 \pm 7.3	0.0006	
Nasal (2.0)	147.3 \pm 10.9	148.9 \pm 16.9	113.8 \pm 8.0	109.2 \pm 8.5	0.0100	
Nasal (2.5)	122.5 \pm 10.2	120.7 \pm 8.0	111.1 \pm 8.8	93.3 \pm 6.3	0.0950	

P values represent the results of posttest comparison with Tukey multiple test.