

MIT Open Access Articles

Three-dimensional endoscopic optical coherence tomography imaging of cervical inlet patch

The MIT Faculty has made this article openly available. **Please share** how this access benefits you. Your story matters.

Citation: Zhou, Chao, Tejas Kirtane, Tsung-Han Tsai, Hsiang-Chieh Lee, Desmond C. Adler, Joseph Schmitt, Qin Huang, James G. Fujimoto, and Hiroshi Mashimo. "Three-Dimensional Endoscopic Optical Coherence Tomography Imaging of Cervical Inlet Patch." *Gastrointestinal Endoscopy* 75, no. 3 (March 2012): 675–677.

As Published: <http://dx.doi.org/10.1016/j.gie.2011.11.009>

Publisher: Elsevier

Persistent URL: <http://hdl.handle.net/1721.1/98867>

Version: Author's final manuscript: final author's manuscript post peer review, without publisher's formatting or copy editing

Terms of use: Creative Commons Attribution-Noncommercial-NoDerivatives





Published in final edited form as:

Gastrointest Endosc. 2012 March ; 75(3): 675–677. doi:10.1016/j.gie.2011.11.009.

Three-dimensional endoscopic optical coherence tomography imaging of cervical inlet patch

Chao Zhou, PhD,

Department of Electrical Engineering and Computer Science and Research Laboratory of Electronics, Massachusetts Institute of Technology, Cambridge, Massachusetts, USA

Tejas Kirtane, MD,

VA Boston Healthcare System, Harvard Medical School, Boston, Massachusetts, USA

Tsung-Han Tsai, MS,

Department of Electrical Engineering and Computer Science and Research Laboratory of Electronics, Massachusetts Institute of Technology, Cambridge, Massachusetts, USA

Hsiang-Chieh Lee, MS,

Department of Electrical Engineering and Computer Science and Research Laboratory of Electronics, Massachusetts Institute of Technology, Cambridge, Massachusetts, USA

Desmond C. Adler, PhD,

LightLab Imaging, St. Jude Medical, Inc, Westford, Massachusetts, USA

Joseph Schmitt, PhD,

LightLab Imaging, St. Jude Medical, Inc, Westford, Massachusetts, USA

Qin Huang, MD,

VA Boston Healthcare System, Harvard Medical School, Boston, Massachusetts, USA

James G. Fujimoto, PhD, and

Department of Electrical Engineering and Computer Science and Research Laboratory of Electronics, Massachusetts Institute of Technology, Cambridge, Massachusetts, USA

Hiroshi Mashimo, MD, PhD

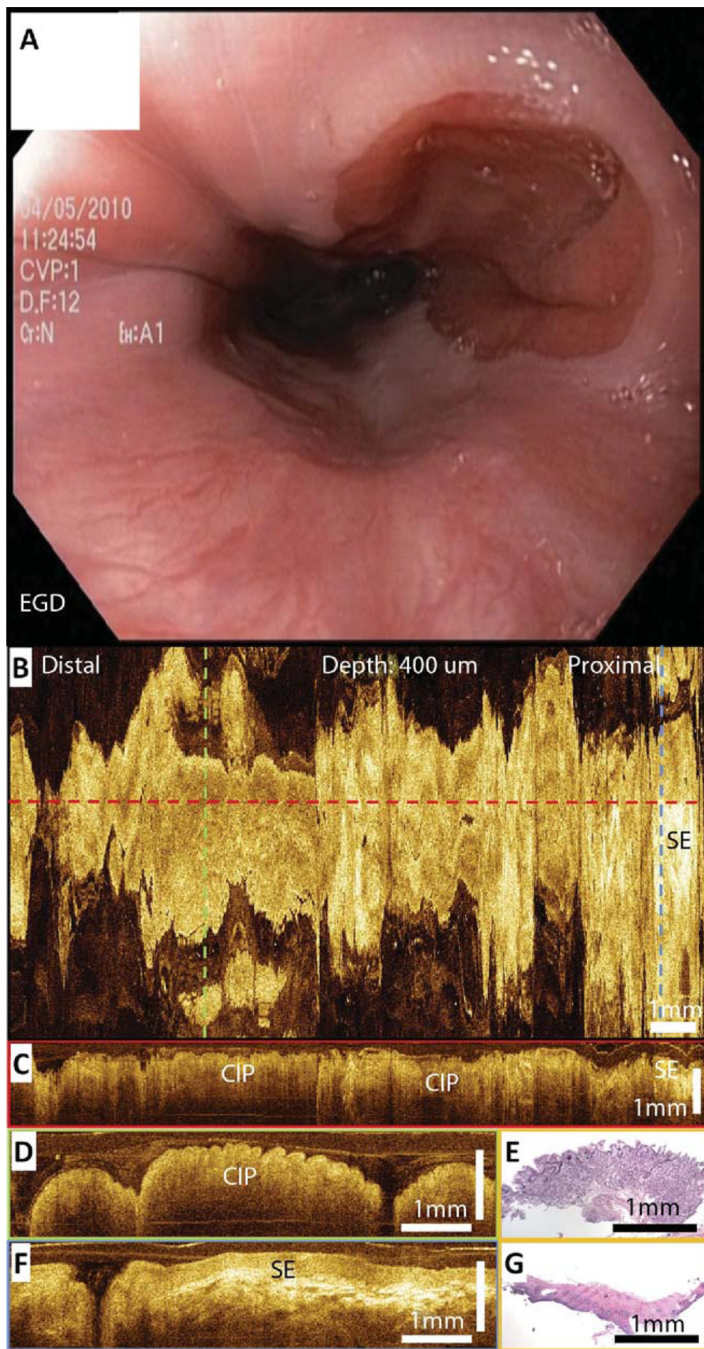
VA Boston Healthcare System, Harvard Medical School, Boston, Massachusetts, USA

A 30-year-old white man with established Barrett's esophagus (BE) and continued symptoms of chronic severe heartburn, persistent cough, throat irritation, and asthma was referred for surveillance EGD at the VA Boston Healthcare System. During retraction of the endoscope, a pink circular lesion (**A**) was observed under white light endoscopy in the upper esophagus (spanning 20–22 cm from the incisors). Three-dimensional endoscopic optical coherence tomography (OCT) images were obtained of the region under direct visualization with white light by passing the probe through the standard accessory channel. An en face projection image (**B**) at 400- μ m depth underneath the tissue surface showed columnar epithelium consistent with a cervical inlet patch (CIP) and surrounding normal squamous epithelium (SE). Cross-sectional OCT images along the probe pull-back direction (**C**) and the probe rotation direction (**D** and **F**) clearly demonstrated columnar and squamous epithelium in the CIP region and the surrounding esophagus, respectively. Biopsy specimens

DISCLOSURE

The following author disclosed financial relationships relevant to this publication: Dr. Fujimoto: royalties from intellectual property owned by MIT and licensed to Light-lab Imaging Inc–St. Jude Medical, royalties from intellectual property owned by MIT and licensed to Carl Zeiss Meditec, scientific advisor to and stock options in Optivue Inc. The other authors disclosed no financial relationships relevant to this publication.

taken from the imaged lesion confirmed the finding of CIP. The OCT features matched representative hematoxylin and eosin histology (**E** and **G**). Both esophageal and extraesophageal symptoms responded to increased antacid therapy.



Acknowledgments

This work was supported by the Veterans Administration and NIH grants R01-CA75289-14 (J.G.F. and H.M.), Air Force Office of Scientific Research contract FA9550-10-1-0063 (J.G.F.), Medical Free Electron Laser Program contract FA9550-10-1-0551 (J.G.F.), and the MIT/CIMIT Medical Engineering Fellowship and Taiwan Merit Scholarship from the National Science Council of Taiwan (T.H.T.).

Commentary

Proton pump inhibitor–refractory GERD and BE prompted an EGD. The authors saw CIP, scanned it with OCT, compared it with SE, and submitted this neat FP. But let’s look a few microns deeper into this case because what lies beneath (and what lies ahead) may surprise you. Heterotopic gastric mucosa, colloquially known as a cervical inlet patch, is more than a congenital endoscopic curiosity. Although most CIPs never come to the attention of the host (or the hurried endoscopist for that matter), they sure seem to have corrosive potential (odynophagia, dysphagia, and—true story—adenocarcinoma). BE and CIP may share an in utero etiology, and patients with coincident BE (like this one) may be at an increased risk of developing dysplastic Barrett’s, both in the proximal and distal esophagus. But let’s change gears because the star of the show here is the novel use of OCT. Just as US images are created by the differential acoustic reflectance of various tissue densities, OCT creates its remarkably impressionistic imagery by the differential reflection of light across ultrastructural cellular elements. Although the OCT probe is about the most highly specialized and temperamental device to ever see the inside of an accessory channel, one cannot argue that realizing the holy grail of the “optical biopsy” is close at hand. OCT is one of several experimental endoscopic imaging techniques (like confocal laser endomicroscopy and endocytoscopy) that take aim at our fairly poor ability to identify luminal dysplasia. Whether OCT will ever make it to an endoscopy center near you is less important than the continued pursuit of better ways to see. This case reminds me of the musings of the American author Og Mandino: “I will love the light for it shows me the way, yet I will endure the darkness because it shows me the stars.”

David Robbins, MD, MSc

Assistant Editor for Focal Points