

MIT Open Access Articles

On the accuracy and reproducibility of a novel probabilistic atlas-based generation for calculation of head attenuation maps on integrated PET/MR scanners

The MIT Faculty has made this article openly available. **Please share** how this access benefits you. Your story matters.

Citation: Chen, Kevin T., David Izquierdo-Garcia, Clare B. Poynton, Daniel B. Chonde, and Ciprian Catana. "On the Accuracy and Reproducibility of a Novel Probabilistic Atlas-Based Generation for Calculation of Head Attenuation Maps on Integrated PET/MR Scanners." *European Journal of Nuclear Medicine and Molecular Imaging* 44, no. 3 (August 29, 2016): 398–407.

As Published: <http://dx.doi.org/10.1007/s00259-016-3489-z>

Publisher: Springer Berlin Heidelberg

Persistent URL: <http://hdl.handle.net/1721.1/106895>

Version: Author's final manuscript: final author's manuscript post peer review, without publisher's formatting or copy editing

Terms of Use: Article is made available in accordance with the publisher's policy and may be subject to US copyright law. Please refer to the publisher's site for terms of use.



On the accuracy and reproducibility of a novel probabilistic atlas-based generation for calculation of head attenuation maps on integrated PET/MR scanners

Kevin T. Chen^{1,2} · David Izquierdo-Garcia¹ · Clare B. Poynton^{1,3,4} · Daniel B. Chonde^{1,5} · Ciprian Catana¹ 

Received: 24 February 2016 / Accepted: 7 August 2016 / Published online: 29 August 2016
© Springer-Verlag Berlin Heidelberg 2016

Abstract

Purpose To propose an MR-based method for generating continuous-valued head attenuation maps and to assess its accuracy and reproducibility. Demonstrating that novel MR-based photon attenuation correction methods are both accurate and reproducible is essential prior to using them routinely in research and clinical studies on integrated PET/MR scanners. **Methods** Continuous-valued linear attenuation coefficient maps (“ μ -maps”) were generated by combining atlases that provided the prior probability of voxel positions belonging to a certain tissue class (air, soft tissue, or bone) and an MR intensity-based likelihood classifier to produce posterior probability maps of tissue classes. These probabilities were used as weights to generate the μ -maps. The accuracy of this probabilistic atlas-based continuous-valued μ -map (“PAC-map”) generation method was assessed by calculating the voxel-wise absolute relative change (RC) between the MR-based and scaled CT-based attenuation-corrected PET images. To assess reproducibility, we performed

pair-wise comparisons of the RC values obtained from the PET images reconstructed using the μ -maps generated from the data acquired at three time points.

Results The proposed method produced continuous-valued μ -maps that qualitatively reflected the variable anatomy in patients with brain tumor and agreed well with the scaled CT-based μ -maps. The absolute RC comparing the resulting PET volumes was 1.76 ± 2.33 %, quantitatively demonstrating that the method is accurate. Additionally, we also showed that the method is highly reproducible, the mean RC value for the PET images reconstructed using the μ -maps obtained at the three visits being 0.65 ± 0.95 %.

Conclusion Accurate and highly reproducible continuous-valued head μ -maps can be generated from MR data using a probabilistic atlas-based approach.

Keywords Attenuation correction · Reproducibility · PET/MR · Probabilistic atlas

Electronic supplementary material The online version of this article (doi:10.1007/s00259-016-3489-z) contains supplementary material, which is available to authorized users.

✉ Ciprian Catana
ccatana@nmr.mgh.harvard.edu

¹ Athinoula A. Martinos Center for Biomedical Imaging, Department of Radiology, Massachusetts General Hospital and Harvard Medical School, Charlestown, MA 02129, USA

² Division of Health Sciences and Technology, Massachusetts Institute of Technology, Cambridge, MA, USA

³ Department of Psychiatry, Massachusetts General Hospital, Boston, MA, USA

⁴ Department of Radiology and Biomedical Imaging, University of California, San Francisco, San Francisco, CA, USA

⁵ Program in Biophysics, Harvard University, Cambridge, MA, USA

Introduction

Recently, there has been growing interest in the development and application of integrated PET/MR scanners. The ability to simultaneously acquire MR and PET data could particularly benefit brain imaging studies [1–3]. However, to accurately quantify PET radiotracer activity, a method to derive subject-specific voxel-wise linear attenuation coefficient (LAC) maps (“ μ -maps”) is needed to perform precise 511-keV photon attenuation correction. The limited physical space inside integrated PET/MR scanners, and the need to reduce the acquisition time and radiation exposure make the implementation and routine use of a standard attenuation correction method that employs a transmission source extremely difficult [1] and alternative strategies are needed for deriving μ -maps from the

MR data. This is a challenging task because the MR images do not reflect the tissue electron density needed for this purpose.

The current MR-based μ -map generation methods can be divided into three main classes: segmentation-based, atlas-based and machine learning-based methods [4, 5], each with its advantages and disadvantages. For example, while segmentation-based and machine learning-based methods provide algorithms for mapping MR intensities to LAC maps, enabling the μ -map produced to take into account variability in the local anatomy, the heterogeneity of MR signal intensities both within the image and across scanners can lead to inaccuracies in μ -map generation and difficulties in the generalization of the method to multiple institutions [6–11]. Segmentation approaches in which a discrete number of LACs are assigned to only a few classes cannot accurately reflect the variable attenuating properties of human tissue, especially at the boundaries between these classes [4, 12, 13]; the accuracy of these methods may also be dependent on the accuracy of the MR pulse sequences used [14]. Atlas-based methods, on the other hand, coupled with an accurate registration method, can warp a predefined atlas, such as that constructed from “gold standard” CT images, to each individual subject [5]. In this case, however, the main drawback is the inability of the atlas to account for local anatomical variations in each subject, such as those encountered in patients who have undergone neurosurgery [4].

We have previously implemented two MR-based μ -map estimation methods using dual-echo ultrashort echo time (UTE) images either alone or in combination with magnetization-prepared rapid acquisition gradient-echo (MPRAGE) morphological MR images to segment the most relevant classes (i.e., bone, soft tissue, and air cavities) [6, 7]. By assigning known LACs to each voxel class, μ -maps were generated from these segmented images. These μ -maps were shown to agree well with those generated by segmenting the corresponding CT images – the “silver standard” approach [6, 7]. However, bias was still present in the PET images reconstructed using these segmented maps compared with those obtained using the “gold standard” – the scaled CT approach [6]. Moreover, for μ -maps to be generated reliably, a method must be not only accurate but also reproducible. In other words, very similar μ -maps should be obtained from different datasets acquired from the same subject in the absence of anatomy-modifying physiological or pathological changes or surgical interventions.

Our first goal in this work was to improve the accuracy of the previously proposed method [7] by extending it to generate probabilistic atlas-based continuous-valued μ -maps (“PAC-maps”) using both atlas registration and a trained probabilistic classifier that incorporates local anatomical information. By combining the strengths of both segmentation-based and atlas-based methods, an MR-based μ -map that agrees well with the “gold standard” and takes into account the subject-specific anatomical variability can be obtained [15].

The second goal of this work was to assess the reproducibility of the PAC-map generation method. To the best of our knowledge, there have been no previous studies that have specifically addressed reproducibility of head MR-based μ -map estimation methods, and other reproducibility studies have only focused on other body regions (e.g., carotids [16]). We investigated the reproducibility by comparing the μ -maps produced from MR data acquired at different time points and the PET images reconstructed using attenuation correction factors derived from these μ -maps.

Materials and methods

Data acquisition

The pipeline for generating the atlas and the μ -map is shown in Fig. 1. Simultaneously acquired PET/MR data and separately acquired head-only CT data from 13 patients with glioblastoma were retrospectively used in this work for the construction of the probabilistic atlas and classifier and for evaluating the accuracy of the PAC-map generation method. There was substantial variability in tumor size (longest axis from 1 to 7 cm) and location, as well as intrasubject and intersubject heterogeneity in the MR images. One subject was removed from this study during method evaluation due to mismatch between the MR and PET data. The reproducibility of the PAC-map method was investigated using data from nine of these subjects who underwent PET/MR examinations at three time points. The study was approved by the local Institutional Review Board.

The imaging data acquisition protocols have been described in detail in by Poynton et al. [7]. Briefly, the CT data were acquired using a LightSpeed QX/I scanner (GE Healthcare) with the following protocol performed within 1 month of the first PET/MR scan: 140 kVp, 150 mAs, 512×512 in-plane voxels (0.492×0.492 mm to 0.668×0.668 mm), $87 - 104$ 2.5-mm² slices [7]. To prevent erroneous tissue class classification during atlas training (which is a possibility when anatomical mismatches between the MR and CT data are present), no patients who underwent surgical procedures that altered the anatomy of the head between the two examinations were enrolled. Similarly, no surgical procedures were performed between the three PET/MR visits. MR and PET data were acquired simultaneously on a MAGNETOM Trio 3-T human MRI scanner (Siemens Healthcare) with a prototype brain PET scanner insert (“BrainPET”). The BrainPET has a transaxial/axial view of 32/19.25 cm, allowing full brain coverage in a single bed position [17]. Dual-echo UTE and T1-weighted MPRAGE MR data (256 slices with 256×256 voxels, 1 mm³ isotropic) were collected for each subject. PET data acquisition in list-mode format was started shortly before administration of about 180 MBq of [¹⁸F]fluorodeoxyglucose (FDG), sorted and compressed

axially in the sinogram space for fast reconstruction [18]. Static frames for the period 40 – 60 min after injection were reconstructed using an ordered-subsets expectation maximization (OSEM) algorithm and corrected for random coincidences [19], detector sensitivity, scatter [20], and attenuation to obtain a final volume of 153 slices with 256×256 voxels, $1.25 \times 1.25 \times 1.25$ mm isotropic. All subsequent analyses for accuracy and reproducibility were performed in the PET space.

Probabilistic atlas and classifier construction

The atlas was constructed following the approach described by Poynton et al. [7]. Briefly, using the FMRIB Software Library program (Oxford Centre for Functional MRI of the Brain) [21, 22], the CT images were rigidly registered (six degrees of freedom, cost function: mutual information) to each subject's intensity-normalized (FreeSurfer normalization [23]) MPRAGE images. Next, the MPRAGE and dual-echo UTE MR images were registered (12 degrees of freedom, cost function: normalized correlation ratio) to the Montreal Neurological Institute (MNI) 152 T1 atlas [24] and the same coregistration parameters were applied to the CT images. Linear interpolation was the method of choice for reslicing all anatomical MR and CT images after coregistration. The registered CT images were then segmented into three distinct tissue classes (soft tissue, bone, and air; Fig. 1a) and the data from all the subjects were combined to generate three probabilistic tissue class atlases. These atlases, when coregistered to the MPRAGE of a new subject, would provide probabilistic a priori information of the tissue class (L_m) segmentation at a given voxel X_n in the form $P(L_m | X_n) = k/N$, where k is the number of occurrences of the tissue class and N is the total number of subjects in the training atlas (Fig. 1c).

To construct the likelihood matrices for each tissue class, the MR images (MPRAGE and two dual-echo UTE images transformed as described by Catana et al. [6]; Fig. 1b) of each subject were masked by the corresponding CT segmentation, and the MR intensity triplets for each voxel were histogrammed to form a 3D histogram. The histograms were aggregated across all subjects to give the probability $P(I_i, I_j, I_k | L_m)$ that a voxel belonging to a certain tissue class L_m would belong to a certain histogram bin $\{I_i, I_j, I_k\}$, where i, j and k represent the three MR images described previously (Fig. 1d). A “leave-one-out” framework was used to construct 13 separate atlases such that none of the subjects was used simultaneously as a test subject and training dataset.

Attenuation map generation

For each test subject, the dual-echo UTE images were first registered to the MPRAGE images using SPM8 [25] with a 12 degrees of freedom transformation and then combined (as

described by Catana et al. [6]) to enhance the signal from bone and air, respectively (Fig. 1e). The constructed atlas was also registered with SPM8 to the subject's MPRAGE images. The posterior probabilities of each tissue class at each voxel were then generated through a Bayesian combination of the a priori atlas information $P(L_m | X_n)$ and the likelihoods of MR image intensities belonging to a certain tissue class $P(I_i, I_j, I_k | L_m)$; Fig. 1f):

$$P(L_m | I_i, I_j, I_k) = \frac{P(I_i, I_j, I_k | L_m) P(L_m | X_n)}{\sum_m (P(I_i, I_j, I_k | L_m) P(L_m | X_n))}$$

The posterior probabilities $P(L_m | I_i, I_j, I_k)$; Fig. 1g) obtained were weighted with the empirically derived LACs of 0, 0.0973 and 0.1593 cm^{-1} (the nonzero values were the mean LACs obtained from the segmentation of the training data-scaled CT maps) for air, soft tissue and bone, respectively, to obtain the continuous-valued LAC values inside a subject-specific MPRAGE-derived head mask (Fig. 1h). Voxels outside the head mask were assigned a LAC of 0. Scaled CT-based μ -maps were obtained from each subject's CT data by scaling the Hounsfield units in the CT images according to the bilinear approach described by Burger et al. [26]. These maps were the “gold standard” for assessing the accuracy of the PAC-map generation method.

Evaluation of the accuracy of the PAC-map generation method

We investigated the bias in PET data quantification by comparing the PET images reconstructed using the μ -maps obtained using the PAC-map method and the scaled CT approach. The radiofrequency coil μ -map (derived from a CT scan of the coil), stationary in the PET field of view, was added to the head μ -map to produce the final μ -map for a subject, which was then smoothed with a gaussian kernel (4 mm full-width at half-maximum) to match the BrainPET scanner's spatial resolution. The smoothed μ -map was forward projected and exponentiated to generate the attenuation correction factor sinogram. To assess the accuracy of the reconstructed PET images, the relative changes (RC) for all brain voxels were calculated using the equation $\text{RC} = 100 \times (\text{PET}_{\text{MR}} - \text{PET}_{\text{CT}}) / \text{PET}_{\text{CT}}$, where PET_{CT} and PET_{MR} denote the values from the PET images reconstructed using scaled CT μ -maps and PAC-maps, respectively, for attenuation correction. The means and standard deviations of the absolute RC values in the brain voxels represent the bias and variability used to evaluate the proposed method. Bland-Altman plots comparing PET_{MR} and PET_{CT} values, converted to standard uptake values (SUVs), for all brain voxels were also generated. The regional accuracy of the proposed method was also evaluated in ten brain regions of interest defined using an automated anatomical

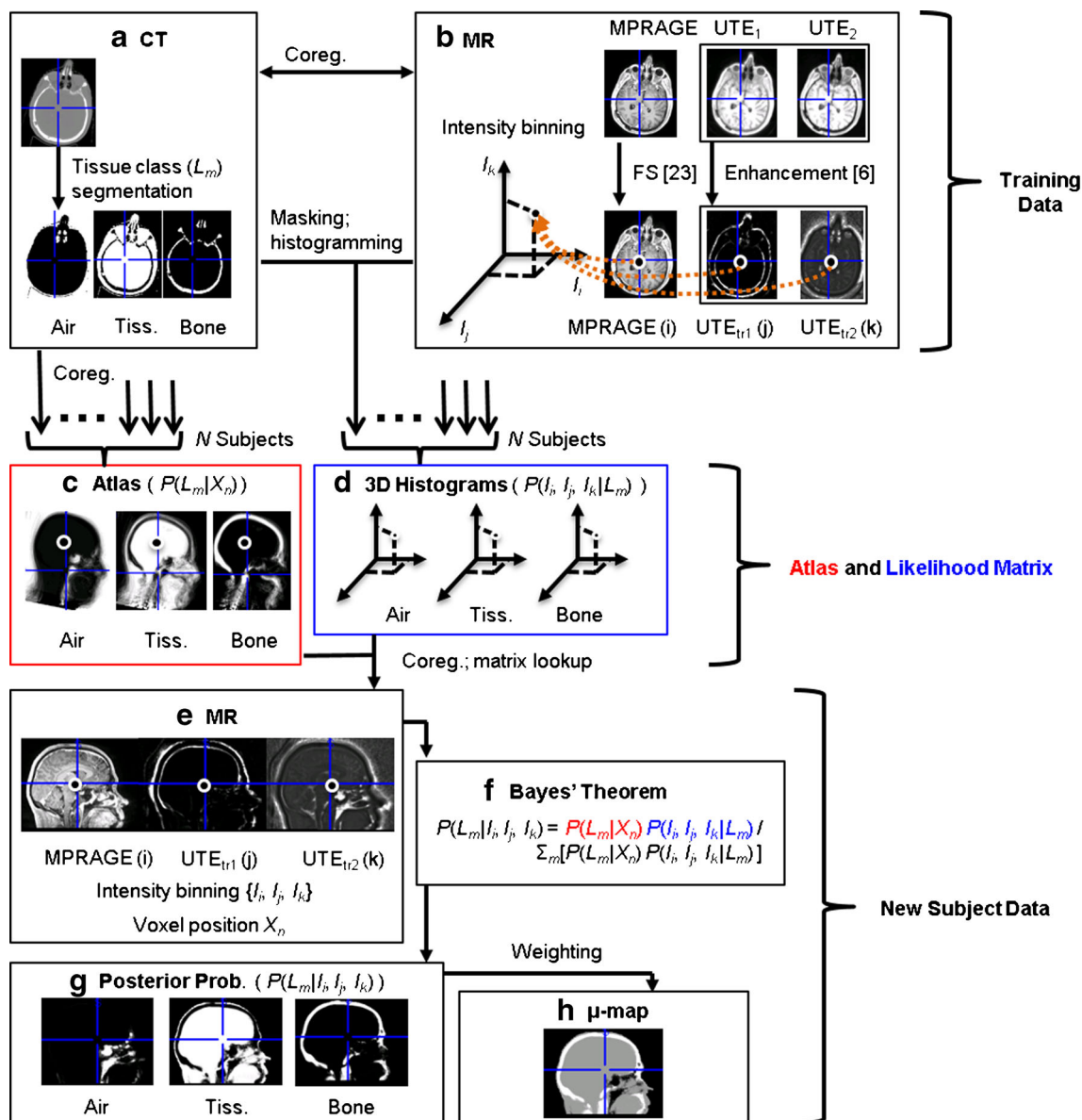


Fig. 1 The μ -map generation pipeline. In addition to the mathematical variables provided in the figure, explanations of the acronyms and abbreviations used are provided in the text. *MPRAGE* magnetization-

prepared rapid acquisition gradient-echo, *UTE* ultrashort echo time, *UTE_{tr}* intensity-transformed UTE, *Coreg.* coregistration

labeling-based atlas [27] and warped using the diffeomorphic anatomical registration using the exponentiated Lie algebra (DARTEL) method in SPM8 [28] to each individual patient and resliced with a nearest-neighbor scheme.

Evaluation of the reproducibility of the PAC-map generation method

Data from nine patients who had undergone three PET/MR scans within a 10-day period were used to assess the reproducibility of the proposed method. The PET emission data acquired at the first visit were reconstructed three times, in each case using a μ -map generated from the coregistered data

acquired at a different visit (the resulting PET images were denoted PET_{MR1} , PET_{MR2} , and PET_{MR3}). Absolute RC values and Bland-Altman plots (PET_{MR1} , PET_{MR2} , and PET_{MR3} values converted to SUVs) were calculated and plotted for the pair-wise comparisons of brain voxels from between the first and second, the first and third, and the second and third visits. Voxel-wise paired *t*-testing was carried out on each of the pair-wise comparisons using SPM8 software. PET emission volumes were first warped into MNI space and smoothed using a $10 \times 10 \times 10$ mm gaussian kernel. We chose a more stringent *p* value of <0.001 , uncorrected for multiple comparisons, as the threshold for this test. Clusters were identified if the voxel number *k* was >5 . In addition, the overall accuracy

of the PET images was quantified for all brain voxels for each patient visit by calculating the RC values between each of the resulting PET images (PET_{MR1} , PET_{MR2} , and PET_{MR3}) and PET_{CT} images. For all three comparisons, the means and standard deviations for absolute RC values in the brain voxels of each subject were computed.

Results

Accuracy of the PAC-map generation method

The CT-based μ -maps and PAC-maps for a representative subject are shown in Fig. 2 (and transverse slices of the μ -maps for two additional subjects are provided in the [Supplementary Data](#)). The PET images reconstructed using the two methods for the same representative subject are shown in the two left panel of Fig. 3 and the RC map is shown in the right panel. The effect of the linear combination of posterior probabilities was most evident in voxels near the sinus (a region with a mixture of multiple tissue types and varying attenuating properties), where the LACs assigned were between the values corresponding to air and soft tissue. Across all subjects, the bias and variability were on average 1.76 % and 2.33 %, respectively. For the specific subject shown in Fig. 3, the bias and variability were 1.38 % and 1.44 %. The Bland-Altman plot for the voxel-based analyses comparing the PET activity reconstructed with the proposed method and the scaled CT method are shown in Fig. 4. The RC values for voxels in each of the ten brain regions of interest are shown in Fig. 5. Relatively greater RC bias and variability were

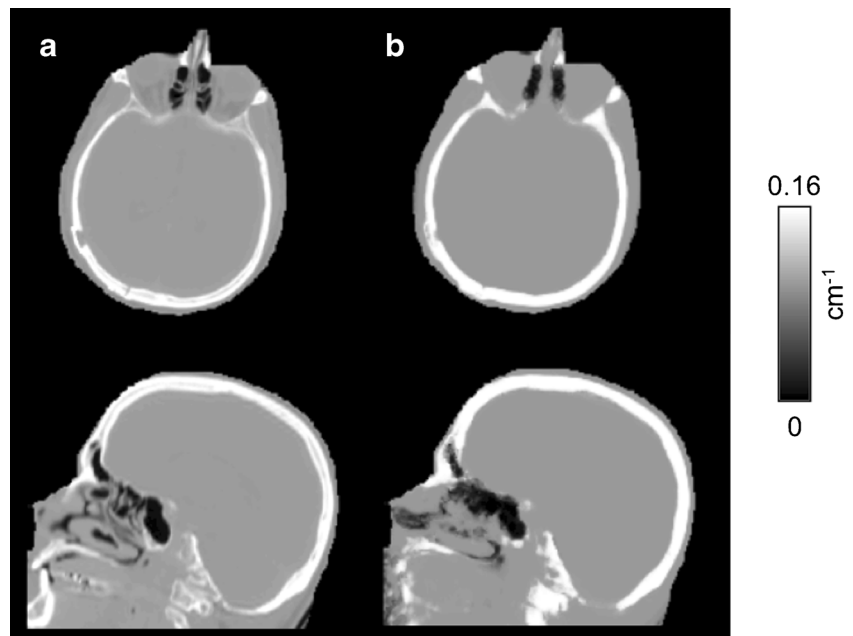
observed in smaller cortical regions or those closer to regions with complex tissue composition, such as the base of the skull and sinus regions.

Reproducibility of the PAC-map generation method

Representative PAC-maps for three visits in one subject are shown in Fig. 6, while the PET reconstructions and the corresponding RC maps are shown in Fig. 7. The μ -maps from the three visits showed good overall agreement. The sinus region, an area with complex tissue class composition, as well as the skull anatomical abnormalities, were also in agreement across visits. PET reconstructions from the three visits also showed similar RCs, with higher values in the cerebellar and inferior cortical regions of the brain consistently across visits. For each of the three visits, the mean bias and variability were 1.73 ± 2.29 %, 1.88 ± 2.41 %, and 1.66 ± 2.22 % for the nine subjects analyzed. For the particular subject shown in Figs. 6 and 7, the values were 1.38 ± 1.44 %, 1.25 ± 1.30 %, and 1.44 ± 1.49 %.

The RC maps from the pair-wise comparisons among the three MR-based PET reconstructions are shown in Fig. 8. All the RC maps in Fig. 8 showed lower absolute values than the maps shown in Fig. 7. Across all subjects, the mean absolute RC for the pair-wise comparisons was 0.65 ± 0.95 %. For the particular subject shown in Fig. 6, the values were 0.71 ± 0.69 %. The Bland-Altman plots for the voxel-based analyses in all three pair-wise comparisons are shown in Fig. 9, with no obvious skew towards the upper or lower portions of the plots. From the voxel-wise paired t tests, only two clusters in the cerebellar region exceeded the threshold ($p < 0.001$ uncorrected) comparing visits

Fig 2 Representative μ -maps, in the sagittal and transverse orientations, derived from the scaled CT method (a) and the PAC-map generation method (b)



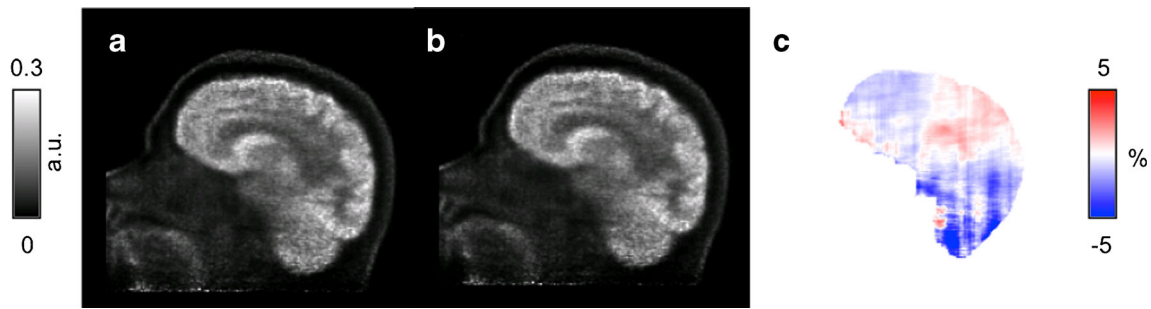


Fig 3 Representative PET images reconstructed with attenuation correction μ -maps derived from the scaled CT method (PET_{CT} , **a**) and the PAC-map generation method (PET_{MR} , **b**). The corresponding relative change map between the two PET reconstructions is shown in **c**

1 and 3; no other significantly different clusters were identified for other pair-wise comparisons.

Discussion

In this work, we assessed the accuracy and reproducibility of a novel PAC-map generation method. Unlike pure atlas-based methods [4], the novel procedure incorporated elements from both atlas-based and segmentation-based methods, a combination of features that yielded a method robust to local anatomical anomalies. In our previous work [7], we used this probabilistic atlas-based approach to produce segmented μ -maps and have shown that these agree well with segmented CT μ -maps. The PAC-map generation method on the other hand has the potential to produce results comparable to the “gold standard” scaled CT method. The μ -maps generated with the proposed method and the corresponding PET reconstructions showed overall agreement with those obtained using the gold standard (Fig. 3); in particular, while atlas-based methods such as those described by Hofmann et al.

[8] and Malone et al. [8, 29] may base LAC assignment heavily on the anatomical information of the atlas and rely on accurate registration to the subject, with the addition of MR intensity-based likelihood matrices that are independent of the subject’s anatomy and physiology, the μ -maps generated by the method described here demonstrated the ability of the method to take into account local anatomical variation, as shown by the anatomical irregularities (i.e., subject-specific anatomy not exhibited in the atlas) apparent in a representative subject (Fig. 2). The sinus regions, with a mix of different tissue types, were also accurately represented. The voxel-based analysis of the RC in brain regions also supported this observation, showing bias and variability within 5 % and even lower values for most of the cerebrum.

Pure machine learning-based methods, such as those employing gaussian mixture models [9, 10] or support vector machines [11], are difficult to generalize to data acquired on different scanners due to variability in MR image intensities. In contrast, the proposed method could relatively easily be applied to data acquired on different scanners. In spite of the MR signal intensity variability among different scanners, customized atlases and likelihood matrices could be constructed from these data to produce continuous μ -maps specifically for each

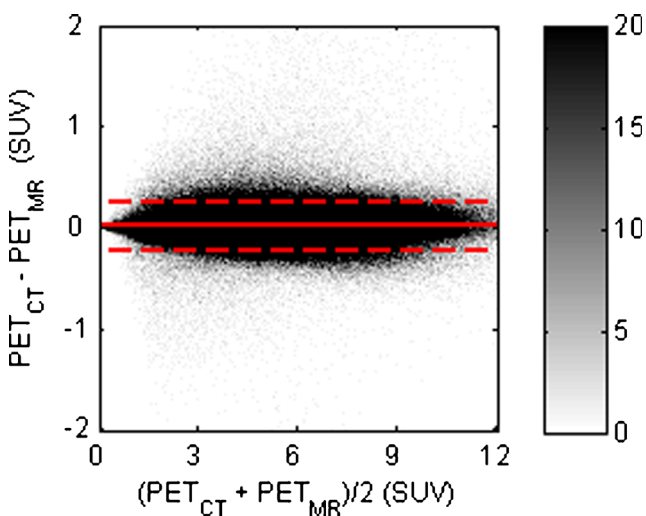


Fig 4 Bland-Altman plot for comparison between PET_{CT} and PET_{MR} (in SUVs) of all brain voxels for all subjects. The difference and average of all voxels were calculated and sorted into a histogram; the *bar* shows the density of voxels in each histogram bin; the *dashed lines* indicate the 2σ limits

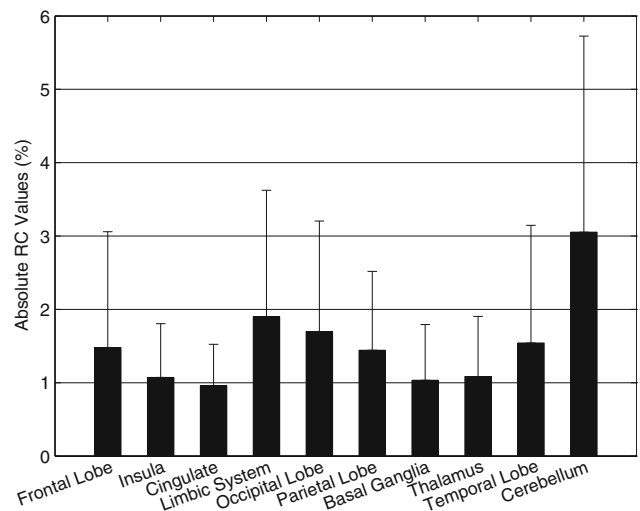
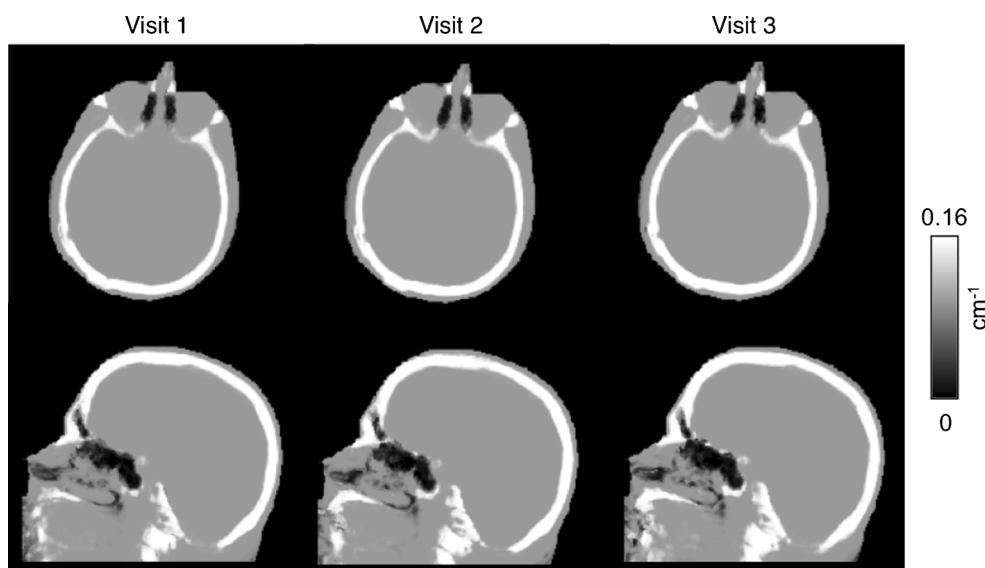


Fig. 5 Mean absolute relative change (RC) values between PET_{CT} and PET_{MR} reconstructions in different regions of the brain

Fig. 6 Representative μ -maps in the sagittal and transverse orientations derived from the PAC-map generation method. The μ -maps are from the same subject but with MR data collected from separate visits in chronological order from left to right. All three visits were used jointly for assessment of the reproducibility of the method



scanner. Moreover, this customizability also allows more flexibility in terms of tissue class selection, or even pulse sequence substitution (such as using zero-echo-time sequences [30] instead of dual-echo UTE). As shown in this work, continuous-valued μ -maps are generated from a hybrid segmentation and atlas-based method using a three-tissue class CT-based segmentation, avoiding reliance on either MR intensity-derived information or atlas prior probabilities alone.

We then investigated the reproducibility of the PAC-map generation method by qualitatively assessing the μ -maps and PET images generated at different time points. The μ -maps from the three visits agreed with each other upon visual

inspection (Fig. 6). Similarly, the PET_{MR} images shown in Fig. 7 (top row) are similar to the PET_{CT} images shown in Fig. 3. Quantitatively, the RC maps shown in Fig. 7 (bottom row) also suggest similar RC patterns in the PET_{MR} data across visits. Minimal bias was observed in the RC maps from comparisons between PET_{CT} and each of the three PET_{MR} values and even lower bias was observed for those calculated from pair-wise comparisons of the three PET_{MR} reconstructions in each subject. The overall voxel-wise agreement among the three visits can also be appreciated from the Bland-Altman plots. Comparing Figs. 4 and 9, it is evident that the distribution of the differences between the pair-wise PET_{MR} values is

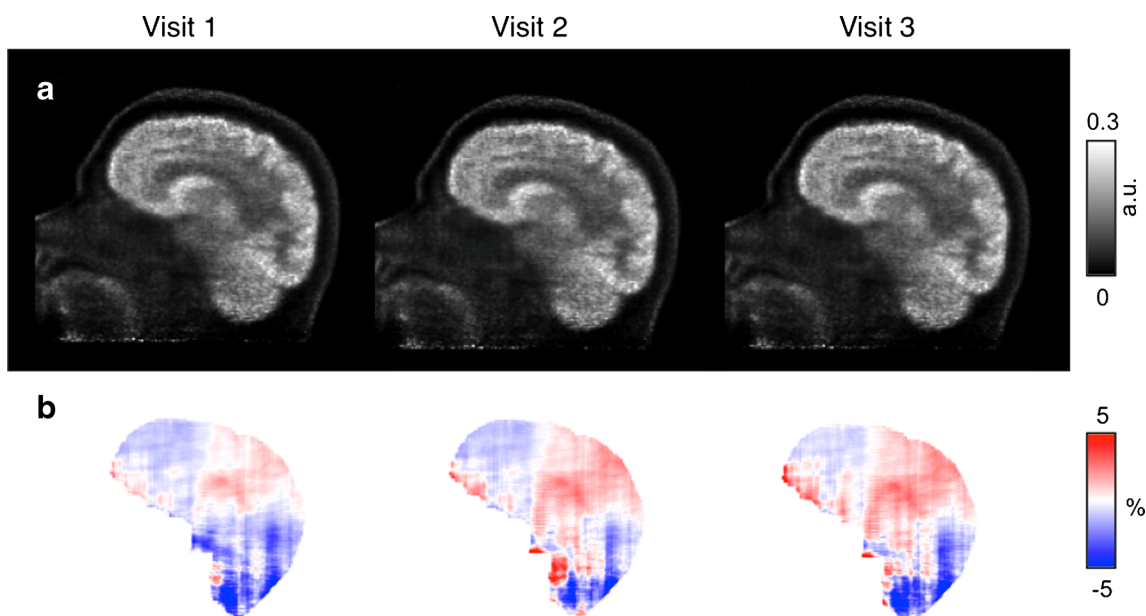


Fig. 7 Data from the same subject at three different visits in chronological order from left to right: **a** PET reconstructions with attenuation correction from μ -maps using the PAC-map generation

method; **b** corresponding relative change maps between reconstructions using the proposed method and the “gold standard” scaled CT method

Fig. 8 Relative change maps from pair-wise comparisons of the PET reconstructions in the same representative subject

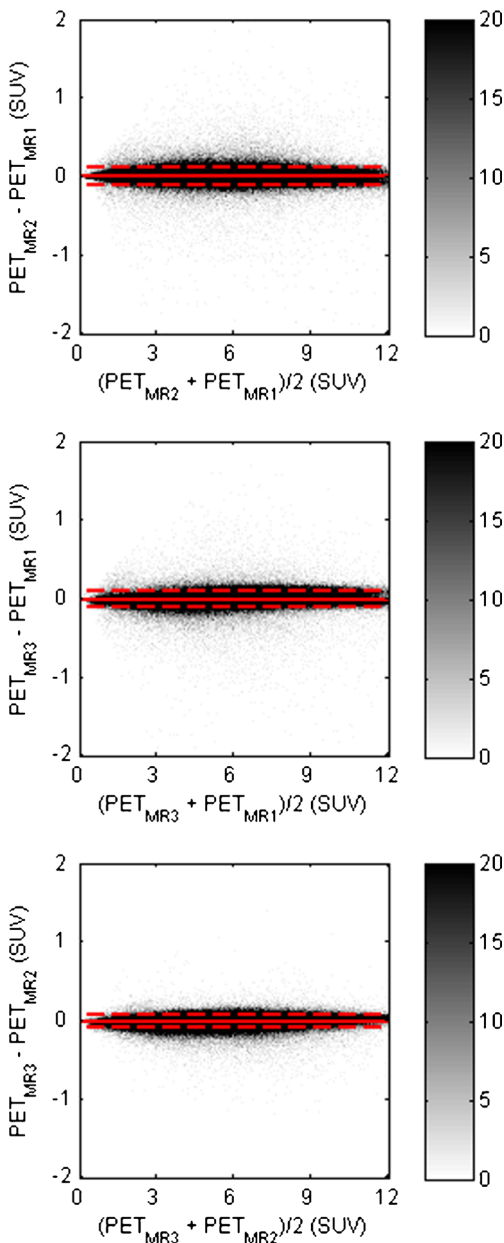
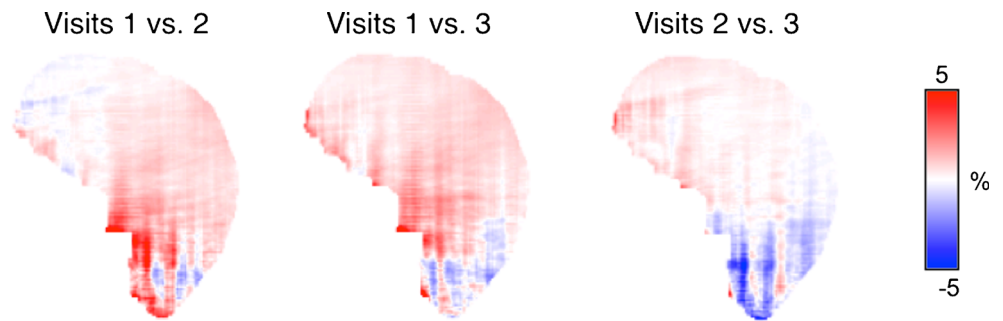


Fig. 9 Bland-Altman plots for pair-wise comparisons of the PET reconstructions (PET_{MR1} , PET_{MR2} , PET_{MR3} ; in standardized uptake values, SUV) of all brain voxels in all subjects, where the MR data were obtained during three different visits. The *dashed lines* indicate the 2σ limits

narrower than that of the differences between the PET_{CT} and PET_{MR} voxels, attesting to the reproducibility of the method. The paired t tests for the pair-wise comparisons of the PET reconstructions showed no significant differences at $p < 0.001$ (uncorrected) except for the two cerebellar clusters identified in one comparison. Although we focused on investigating the impact of PAC-maps on the static PET reconstructions (similar to those routinely used clinically), their influence on the parametric images generated from the dynamic data is likely more complex and warrants further investigation.

In principle, the proposed μ -map generation method could be extended to other body regions. One obvious challenge is obtaining good-quality MR data over a larger field of view using dual-echo UTE sequences. Additionally, the coregistration task would be more challenging because of the higher intersubject variability in organs and body shape and size. To address this issue, either more accurate coregistration methods or patch-based methods [31] could be used.

One limitation of the current implementation is that it is challenging to accurately characterize all the tissue types for atlas and likelihood matrix generation. For example, in the probabilistic three-tissue compartment segmented atlas used in this work, bone marrow was classified together with cortical bone although it has different attenuating properties. However, similar to other methods that use more than three tissue classes for segmentation [12, 32], the atlas generation method could also be modified to allow for a larger number of tissue classes and to select different Hounsfield unit cut-off values for various tissue classes. For example, although μ -maps generated using atlases composed of five tissue classes demonstrate promising results (data not shown), one goal of this work was to assess the feasibility of generating continuous-valued μ -maps from the combination of segmentation and atlas-based approaches and thus, similar to other works that have evaluated the effect of tissue class selection [33, 34], further studies are needed to determine the optimal combination. Selection of proper LAC values to weigh the posterior probabilities may also be important in obtaining the optimal combination for μ -map generation. We tried to assess the accuracy of μ -maps generated with varying bone and soft tissue LAC weights, but observed only marginal improvement in accuracy compared to the current LAC selection (data not shown).

Another limitation of the proposed method is in the way regions with complex tissue composition are represented. As shown in Fig. 5, regions adjacent to the base of the skull or sinuses have in general higher bias and variability than other regions. The optimal combination suggested above could further improve the accuracy of the proposed method, reducing RC bias and variability compared with those reported using the current combination. Finally, the limited number of datasets used to generate the atlas and likelihood matrix could have affected the reliability of the method, as the a priori information from which the tissue class posterior probabilities were derived highly depended on the anatomy of the training dataset.

Conclusion

In integrated PET/MRI scanners, an accurate and reproducible MR-based method to generate μ -maps similar to those obtained using the “gold standard” is needed for quantitative PET studies. Here, we introduced a continuous-valued μ -map generation method to extend our previous work in which a μ -map with a limited number of discrete tissue classes was proposed. This probabilistic atlas-based approach combines the strengths of voxel-based segmentation methods and atlas-based methods to take into account local anatomical variability. This μ -map generation method was shown to be accurate to within 2 % compared with the CT-based method and reproducible within 1 %.

Compliance with ethical standards

Funding This work was funded by NIH grant 1R01EB014894-01A1 and by the U.S. Department of Defense (DoD) through the National Defense Science & Engineering Graduate Fellowship (NDSEG) Program.

Conflicts of interest None.

Ethical approval All procedures performed in studies involving human participants were in accordance with the ethical standards of the institutional and/or national research committee and with the 1964 Declaration of Helsinki and its later amendments or comparable ethical standards.

References

- Herzog H, Pietrzyk U, Shah NJ, Ziemons K. The current state, challenges and perspectives of MR-PET. *Neuroimage*. 2010;49:2072–82. doi:10.1016/j.neuroimage.2009.10.036.
- Catana C, Drzezga A, Heiss WD, Rosen BR. PET/MRI for neurologic applications. *J Nucl Med*. 2012;53:1916–25. doi:10.2967/jnumed.112.105346.
- Catana C, Guimaraes AR, Rosen BR. PET and MR imaging: the odd couple or a match made in heaven? *J Nucl Med*. 2013;54:815–24. doi:10.2967/jnumed.112.112771.
- Bezrukov I, Mantlik F, Schmidt H, Scholkopf B, Pichler BJ. MR-based PET attenuation correction for PET/MR imaging. *Semin Nucl Med*. 2013;43:45–59. doi:10.1053/j.semnuclmed.2012.08.002.
- Hofmann M, Pichler B, Scholkopf B, Beyer T. Towards quantitative PET/MRI: a review of MR-based attenuation correction techniques. *Eur J Nucl Med Mol Imaging*. 2009;36 Suppl 1:S93–104. doi:10.1007/s00259-008-1007-7.
- Catana C, van der Kouwe A, Benner T, Michel CJ, Hamm M, Fenchel M, et al. Toward implementing an MRI-based PET attenuation-correction method for neurologic studies on the MR-PET brain prototype. *J Nucl Med*. 2010;51:1431–8. doi:10.2967/jnumed.109.069112.
- Poynton CB, Chen KT, Chonde DB, Izquierdo-Garcia D, Gollub RL, Gerstner ER, et al. Probabilistic atlas-based segmentation of combined T1-weighted and DUTE MRI for calculation of head attenuation maps in integrated PET/MRI scanners. *Am J Nucl Med Mol Imaging*. 2014;4:160–71.
- Hofmann M, Steinke F, Scheel V, Charpiat G, Farquhar J, Aschoff P, et al. MRI-based attenuation correction for PET/MRI: a novel approach combining pattern recognition and atlas registration. *J Nucl Med*. 2008;49:1875–83. doi:10.2967/jnumed.107.049353.
- Johansson A, Karlsson M, Nyholm T. CT substitute derived from MRI sequences with ultrashort echo time. *Med Phys*. 2011;38:2708–14. doi:10.1118/1.3578928.
- Larsson A, Johansson A, Axelsson J, Nyholm T, Asklund T, Riklund K, et al. Evaluation of an attenuation correction method for PET/MR imaging of the head based on substitute CT images. *MAGMA*. 2013;26:127–36. doi:10.1007/s10334-012-0339-2.
- Navalpakkam BK, Braun H, Kuwert T, Quick HH. Magnetic resonance-based attenuation correction for PET/MR hybrid imaging using continuous valued attenuation maps. *Invest Radiol*. 2013;48:323–32. doi:10.1097/RLI.0b013e318283292f.
- Berker Y, Franke J, Salomon A, Palmowski M, Donker HC, Temur Y, et al. MRI-based attenuation correction for hybrid PET/MRI systems: a 4-class tissue segmentation technique using a combined ultrashort-echo-time/Dixon MRI sequence. *J Nucl Med*. 2012;53:796–804. doi:10.2967/jnumed.111.092577.
- Keereman V, Fierens Y, Broux T, De Deene Y, Lonneux M, Vandenberghe S. MRI-based attenuation correction for PET/MRI using ultrashort echo time sequences. *J Nucl Med*. 2010;51:812–8. doi:10.2967/jnumed.109.065425.
- Ladefoged CN, Benoit D, Law I, Holm S, Kjaer A, Hojgaard L, et al. Region specific optimization of continuous linear attenuation coefficients based on UTE (RESOLUTE): application to PET/MR brain imaging. *Phys Med Biol*. 2015;60:8047–65. doi:10.1088/0031-9155/60/20/8047.
- Izquierdo-Garcia D, Hansen AE, Förster S, Benoit D, Schachoff S, Fürst S, et al. An SPM8-based approach for attenuation correction combining segmentation and nonrigid template formation: application to simultaneous PET/MR brain imaging. *J Nucl Med*. 2014;55:1825–30. doi:10.2967/jnumed.113.136341.
- Bini J, Robson PM, Calcagno C, Eldib M, Fayad ZA. Quantitative carotid PET/MR imaging: clinical evaluation of MR-attenuation correction versus CT-attenuation correction in (18)F-FDG PET/MR emission data and comparison to PET/CT. *Am J Nucl Med Mol Imaging*. 2015;5:293–304.
- Schlemmer HP, Pichler BJ, Schmand M, Burbar Z, Michel C, Ladebeck R, et al. Simultaneous MR/PET imaging of the human brain: feasibility study. *Radiology*. 2008;248:1028–35. doi:10.1148/radiol.2483071927.
- Hong IK, Chung ST, Kim HK, Kim YB, Son YD, Cho ZH. Ultra fast symmetry and SIMD-based projection-backprojection (SSP) algorithm for 3-D PET image reconstruction. *IEEE Trans Med Imaging*. 2007;26:789–803. doi:10.1109/TMI.2002.808360.
- Byars LG, Sibomana M, Burbar Z, Jones J, Panin V, Barker WC, et al. Variance reduction on randoms from delayed coincidence histograms for the HRRT. *IEEE Nucl Sci Symp Conf Rec*. 2005;5:2622–6. doi:10.1109/NSSMIC.2005.1596876

20. Watson CC. New, faster, image-based scatter correction for 3D PET. *IEEE Trans Nucl Sci.* 2000;47:1587–94. doi:10.1109/23.873020.
21. Jenkinson M, Smith S. A global optimisation method for robust affine registration of brain images. *Med Image Anal.* 2001;5:143–56.
22. Smith SM, Jenkinson M, Woolrich MW, Beckmann CF, Behrens TE, Johansen-Berg H, et al. Advances in functional and structural MR image analysis and implementation as FSL. *Neuroimage.* 2004;23 Suppl 1:S208–19. doi:10.1016/j.neuroimage.2004.07.051.
23. Dale AM, Fischl B, Sereno MI. Cortical surface-based analysis. I. Segmentation and surface reconstruction. *Neuroimage.* 1999;9:179–94.
24. Fonov V, Evans AC, Botteron K, Almli CR, McKinstry RC, Collins DL. Unbiased average age-appropriate atlases for pediatric studies. *Neuroimage.* 2011;54:313–27. doi:10.1016/j.neuroimage.2010.07.033.
25. Ashburner J, Friston K. Spatial transformation of images. In: Frackowiak RS, Friston K, Frith CD, Dolan RJ, Mazziotta JC, editors. *Human brain function.* San Diego: Academic Press; 1997. p. 43–58.
26. Burger C, Goerres G, Schoenes S, Buck A, Lonn AH, Von Schulthess GK. PET attenuation coefficients from CT images: experimental evaluation of the transformation of CT into PET 511-keV attenuation coefficients. *Eur J Nucl Med Mol Imaging.* 2002;29:922–7. doi:10.1007/s00259-002-0796-3.
27. Tzourio-Mazoyer N, Landeau B, Papathanassiou D, Crivello F, Etard O, Delcroix N, et al. Automated anatomical labeling of activations in SPM using a macroscopic anatomical parcellation of the MNI MRI single-subject brain. *Neuroimage.* 2002;15:273–89. doi:10.1006/nimg.2001.0978.
28. Ashburner J. A fast diffeomorphic image registration algorithm. *Neuroimage.* 2007;38:95–113. doi:10.1016/j.neuroimage.2007.07.007.
29. Malone IB, Ansorge RE, Williams GB, Nestor PJ, Carpenter TA, Fryer TD. Attenuation correction methods suitable for brain imaging with a PET/MRI scanner: a comparison of tissue atlas and template attenuation map approaches. *J Nucl Med.* 2011;52:1142–9. doi:10.2967/jnumed.110.085076.
30. Delso G, Wiesinger F, Sacolick LI, Kaushik SS, Shanbhag DD, Hullner M, et al. Clinical evaluation of zero-echo-time MR imaging for the segmentation of the skull. *J Nucl Med.* 2015;56:417–22. doi:10.2967/jnumed.114.149997.
31. Torrado-Carvajal A, Herraiz JL, Alcaín E, Montemayor AS, García-Canamaque L, Hernández-Tamames JA, et al. Fast patch-based pseudo-CT synthesis from T1-weighted MR images for PET/MR attenuation correction in brain studies. *J Nucl Med.* 2016;57:136–43. doi:10.2967/jnumed.115.156299.
32. Fei BW, Yang XF, Nye JA, Aarsvold JN, Raghunath N, Cervo M, et al. MR/PET quantification tools: registration, segmentation, classification, and MR-based attenuation correction. *Med Phys.* 2012;39:6443–54. doi:10.1118/1.4754796.
33. Akbarzadeh A, Ay MR, Ahmadian A, Alam NR, Zaidi H. MRI-guided attenuation correction in whole-body PET/MR: assessment of the effect of bone attenuation. *Ann Nucl Med.* 2013;27:152–62. doi:10.1007/s12149-012-0667-3.
34. Martínez-Moller A, Souvatzoglou M, Delso G, Bundschuh RA, Chefd'hotel C, Ziegler SI, et al. Tissue classification as a potential approach for attenuation correction in whole-body PET/MRI: evaluation with PET/CT data. *J Nucl Med.* 2009;50:520–6. doi:10.2967/jnumed.108.054726.