

**Abdominal Vacuum Lift as an Aid to Diagnosing  
Abdominal Adhesions**

by

Julius Strauss

Submitted to the Department of Mechanical  
Engineering in Partial  
Fulfillment of the Requirements for the  
Degree of

Bachelor of Science

at the

Massachusetts Institute of Technology

June 2006

© 2006 Julius Strauss  
All rights reserved

The author hereby grants to MIT permission to reproduce and to  
distribute publicly paper and electronic copies of this thesis document in whole or in part  
in any medium now known or hereafter created.

Signature of Author.....

Department of Mechanical Engineering  
May 12, 2006

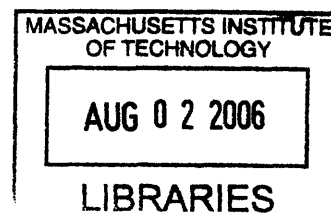
Certified by .....

Ernesto E. Blanco  
Thesis Supervisor

**ARCHIVES**

Accepted by .....

John H. Lienhard V  
Chairman, Undergraduate Thesis Committee



# **Abdominal Vacuum Lift as an Aid to Diagnosing Abdominal Adhesions**

by

Julius Strauss

Submitted to the Department of Mechanical Engineering  
on May 12, 2006 in partial fulfillment of the  
requirements for the degree of Bachelors of science in  
Mechanical Engineering

## **Abstract**

The internal organs are designed to move freely and slide over one another during normal body movement. The abdominal organs, however, have a tendency to adhere to the abdominal cavity (peritoneum) and other abdominal organs after surgery or infection. These adhesions can cause pain, discomfort, inflammation, anxiety, depression, problems with conception, trouble eating, and decreased immune function. There are around 300,000 hospital admissions in the U.S. every year for patients due to adhesions. Part of the problem is that there is no suitable method to diagnose adhesions. Recently there have been a number of studies which suggest that measuring visceral slides under ultrasound using exaggerated respiration may prove to be very promising in diagnosing adhesions non invasively. Yet there are still weaknesses in the predictive power of these procedures. For such procedures to be successfully implemented into clinical medicine and offer non invasive methods to diagnosing adhesions, they must first be able to offer higher percentage predictive values. We have worked on a number of models of an external abdominal vacuum system which we believe will increase the accuracy and predictive values of measuring visceral slides under ultrasound using exaggerated respiration.

Thesis Supervisor: Ernesto E. Blanco

Title: Adjunct Professor of Mechanical Engineering

## **Background (An In- depth Overview of Adhesions)**

### **Physical problems and symptoms:**

The internal organs are designed to move freely and slide over one another during normal body movement. For instance, the intestines are very mobile and move via peristaltic motion. In general, body movements such as bending and stretching require that the organs have the ability to move in order to allow flexibility to the body's torso. The abdominal organs, however, have a tendency to adhere to the abdominal cavity (peritoneum) and other abdominal organs after surgery. When internal organs adhere to one another the body's flexibility is lost. Body movements and normal organ functions can then cause pulling and stretching of the organs which in turn creates pain.

Adhesions may cause a number of other problems as well. The intestines can become twisted, pinched, or blocked by scar tissue, stopping the flow of food through the intestines. If a complete obstruction results, severe pain, nausea, and vomiting can occur. The intestines can also have their blood supply hindered by scar tissue causing a lack of oxygen to the organ, again resulting in pain. In extreme cases, adhesions may form fibrous bands around a segment of an intestine. This constricts the blood flow and leads to tissue death.

Adhesions can also cause thickening of tissues. Thickening of normally flexible tissues can cause discomfort when these tissues are required to expand and stretch. This occurs in and around the colon as bowel movements pass through it, and pain occurs when this thickened tissue is unable to stretch. A similar effect can be found in and around the uterus and vagina which require flexibility during sexual intercourse. When thickening of these structures occur it can cause discomfort or even pain.

The symptoms of adhesions change from patient to patient and there is no set guide of defined symptoms. Constipation or obstruction sometimes occurs. Partial obstruction can lead to alternating diarrhea and constipation. These adhesions may also trigger waves of cramp like pain in you stomach. This pain can last for seconds or minutes and it often worsens if you eat food, which increases the activity of the stomach. Vomiting often relieves the pain. Intestinal adhesions may cause the stomach to become tender and progressively bloated. If a blockage persists the patient may develop a fever. Further progression can tear the patients intestinal wall and allow bowel contents to pour into your abdominal cavity.

Adhesions in women can lead to changes in the menstrual cycle, infertility, and pain during sexual intercourse. Pelvic adhesions may involve an organ within the pelvis, such as the uterus, ovaries, fallopian tubes, or bladder, and usually occur after surgery. Pelvic inflammatory disease results from an infection, usually due to a sexually transmitted disease, that frequently leads to adhesions within the fallopian tubes. A woman's eggs pass through her fallopian tubes into her uterus for reproduction. Fallopian adhesions can lead to infertility and increased incidence of ectopic pregnancy in which a fetus develops outside the uterus.

Adhesions can also effect the heart. Scar tissue may form within the membranes that surround the heart. These membranes are known as the pericardial sac. The presence of these scar tissues restrict heart function. Pericardial adhesions may cause chest pain. Infections such as rheumatic fever may lead to adhesions forming on heart valves and leading to decreased heart efficiency. Adhesions may also form above the liver. These adhesions may cause pain with deep breathing. They can form in the hand or around the spine.

Adhesions can cause inflammation resulting in discomfort. In fact, the bodies own inflammation response to these abnormal tissues could cause them to swell and cause discomfort. Adhesions can also cause indirect symptoms such as anxiety, depression, problems with conception, trouble eating, and decreased immune function.

### **Forms of Adhesions:**

Adhesions can be found in many forms. Some adhesions appear loose, filmy and flexible like cellophane. Other adhesions can be very dense and inflexible like leather. Still others adhesions produce very hard thickening of the tissues. This is especially common with other disorders that can invade the surrounding tissue such as endometriosis or inflammatory bowel diseases. Most severe of all are when adhesions cause organs to not just adhere to one another but actually fuse together.

### **Causes:**

All of the abdominal and pelvic organs, except the ovaries, are at least partially wrapped in a clear membrane called the peritoneum. When the peritoneum is traumatized during surgery or in some other way such as infection or disease, the site of the trauma becomes inflamed. Inflammation is normal and in fact is part of the healing process. But inflammation also contributes to adhesion formation by encouraging the development of fibrous bands of scar tissue.

Normally, these fibrin bands eventually dissolve through a biochemical process called fibrinolysis, and the traumatized site continues to heal. But sometimes the nature of the surgery or infection results in decreased blood flow to these areas called ischemia, which can suppress fibrinolysis. If the fibrin bands do not dissolve, they may develop into adhesions that grow to connect or bind together pelvic organs or tissues that normally are separate.

Previous surgery is by far the most common cause of adhesions. Everything from cutting, powder from surgical gloves, lint from sponges and suturing can cause enough irritation to form scar tissue which is the basis for adhesions. During surgery blood present in the operating field as well as blood from other tissues can cause adhesions to form. Also bleeding can often occur after surgery is completed. In addition, constricting or pinching of blood vessels causing restricted blood flow encourages the formation of adhesions. Other contributing conditions include trauma, radiation therapy, pelvic inflammatory disease and infection. All of these can promote and encourage the formation of adhesions.

A number of gynecological procedures and diseases are also associated with adhesions including hysterectomies, cesarean sections, ovarian surgeries, dilation and curettage, myomectomy, reconstructive tubal surgery, and endometriosis.

A hysterectomy is a procedure to remove the uterus, or womb, and may also be performed in conjunction with the removal of one or both ovaries. Adhesions that form after this procedure may attach to the small intestine, causing pelvic pain, constipation, and sometimes a more serious complication, such as small bowel obstruction (blockage of the intestine that limits or stops passage of its contents). Bowel obstruction may occur soon after surgery or develop many years later.

Adhesions may also form after a birth performed by cesarean section. These adhesions typically do not cause pain. They can sometimes make subsequent cesarean sections more difficult, however,

because the physician must cut through these adhesions to get to the uterus and the baby, which can increase the length of the procedure and the amount of time the mother and baby are under anesthesia.

Ovarian surgery is often performed to remove ovarian cysts (small sacs filled with fluid that grow on the ovaries). The ovary is one of the most common sites where adhesions form. Adhesion formation after surgery can lead to pelvic pain, pain during intercourse, and infertility.

Dilation and curettage is a surgical procedure in which the doctor widens (dilates) the opening of the cervix and scrapes away tissue from the lining of the uterus. Adhesions may form after a dilation and curettage in response to the trauma inflicted on the uterine wall.

Myomectomy is a surgical procedure to remove fibroids from the uterus. Adhesion formation where the incision is made on the uterus is a common complication of the procedure. These adhesions can also affect the ovaries and fallopian tubes, potentially causing infertility and pelvic pain.

The repair of blocked fallopian tubes is a delicate procedure that often includes the removal of existing adhesions. Unfortunately, the surgery itself can also lead to the formation of new adhesions and the complications they can cause, such as pelvic pain and infertility.

Endometriosis is a condition in women where small bits of the lining of the uterus escape through the fallopian tubes and enter the abdominal cavity. These cells then become implanted on the surface of the abdominal organs causing them to adhere to one another. In addition, the endometrial tissue remains hormonally active even after leaving the uterus. Therefore this tissue has the potential to cause pain and bleeding in the abdomen. Also as the tissue grows on the ovaries, fallopian tubes, and uterine wall sheds, scar tissue can form. This can block the fallopian tubes, disrupt the shape of the uterus, or interfere with ovulation. Endometriosis can cause painful periods, pain during ovulation, deep, stabbing pain during intercourse, painful bowel movements, painful urination, and heavy bleeding or bleeding between periods. Endometrial tissue can also cause pelvic adhesions, in which organs vital to reproduction stick together. As a result, many women suffering from endometriosis cannot become pregnant.

#### **Treatment:**

Once adhesions are formed, there is no current medicine that can dissolve them. Treatment of the symptoms with pain, anti-nausea or hormonal medications for endometriosis are sometimes helpful. The main treatment for adhesions, however, is their surgical removal, known as adhesiolysis. This requires cutting the connections between the abdominal organs to once again separate them. In the past this was done using an open surgical incision, but since surgery itself is the cause of adhesions, surgical operations to remove adhesions were often unsuccessful as the adhesions simply re-formed.

Now with the introduction of laparoscopic surgery, the adhesions can be divided using laparoscopic techniques with lesser re-formation. Still, Laparoscopic surgery is very specialized and requires a great deal of advanced laparoscopic surgical skill. It also requires specialized surgical instruments including the laparoscopic and needlescopic instrumentation and the use of lasers and ultrasonic dissection devices. For these reasons, many surgeons do not perform surgical treatment of adhesions.

Also recently a number of soft tissue physical therapies have been developed to help patients with the symptoms of adhesions. Some of these, such as the Wurn Technique administered by Clear Passage Therapies clinics are believed to be very good at assuaging these symptoms. In two scientific studies the Wurn technique was found to decrease the pain of adhesions and even increase the function of reproductive organs. These studies are available at <http://www.medscape.com/viewarticle/480429>.

## **Laparoscopic Adhesiolysis**

Laparoscopic lysis of adhesions or laparoscopic adhesiolysis is the primary treatment for Adhesions. For the operation, the patient is placed under general anesthesia in an advanced laparoscopic Operating Room where the necessary instruments are available. A number of small holes ranging between and 3 to 10 mm (1/8 to 3/8 of an inch) are made in various locations on the abdomen. Small tubes, or trocar sleeves, are placed through these small incisions to keep the skin, fatty tissue, and muscle open for the introduction of instruments into the abdominal space. Carbon dioxide is pumped in through one of these tubes to inflate the abdomen giving the surgeons room to work. A laparoscope is introduced through one of these tubes, which is attached to a powerful light system and digital camera system. This allows for the intra-abdominal space to be viewed on a television monitor alongside the patient. The surgical team, which generally consists of the primary surgeon, an assistant surgeon, a physician's assistant, and a scrub nurse, then carry out the operation. The operation consists of dividing the abnormal connections (adhesions) between the various intra-abdominal organs. Depending on the severity of the adhesions, this operation may last anywhere between 1-6 hours with a common average time being approximately 2 hours. Once all of the adhesions are divided and the intra-abdominal space is completely free, the small tubes are removed and the small skin incisions are sewn shut using absorbable suture on the skin that does not need to be removed.

Recovery is variable depending on a variety of patient characteristics, including the severity of the adhesions. A hospital stay of between 1-3 days is typical. The hospitalization is required for observation while the patient returns to eating and activity to be sure that there are no problems that develop and to see that the internal organs, primarily the stomach and intestines, return to their normal function now that they are freed from the adhesions.

Risks of laparoscopic lysis of adhesions include general medical complications, general surgical complications, and problems specific to adhesiolysis. General medical complications include heart attack, pneumonia, blood clots, and stroke, along with many other medical problems. These are dependent on the patient's overall medical history and are generally the result of the stress placed on the patient's system by the surgery itself and primarily by anesthesia. This requires a complete medical evaluation by a person's doctor to determine their readiness for surgery. A person who has multiple medical problems including previous heart attacks, lung problems, diabetes, or other problems have increased risk of undergoing any type of surgery and require medical stabilization prior to their surgery. People who are otherwise healthy have very little risk of general medical complications.

Complications that are common to any surgical procedure include bleeding, infection, and incisional hernias. Bleeding can occur during or after the operation, and in rare cases may require transfusion or re-operation to control bleeding. Bleeding complications are somewhat reduced with adhesion surgery because generally adhesions contain minimal blood vessels, and major organs are not being cut into. Infection can result after any operation. Infection can result inside the abdomen causing abscess formation. This also is extremely rare, but can require that a catheter be placed to drain infection or re-

operation to drain infection may be necessary. Adhesiolysis carries a very low risk of infectious complications, again because the internal organs are not being entered directly. Infection at the small skin incisions is possible but these are rare due to their very small size. When infection at an incision occurs it is generally easily resolved with oral antibiotics, again because the incisions are so small. Whenever the abdominal wall is cut through during a surgical operation it must heal to re-form a complete abdominal wall. When healing of the muscular layer is incomplete, a hole can result causing herniation of the intra-abdominal contents out through that hole. This is called an incisional hernia. This is possible with laparoscopic incisions although it is rare because of their small size. When it occurs, it will generally require re-operation to repair the muscle layer under the incision at a later date. Hernias can present significant problems if intra-abdominal organs, such as intestines, become stuck in the hole in the muscle in which case emergency surgery is required to repair hernia. Fortunately, laparoscopy has greatly reduced the incidence of this complication as well.

The most important complication that relates specifically to the adhesion surgery is injury to the organs on which the adhesions have formed. The extent of adhesions and the type of adhesions found determines the amount of risk. Loose filmy adhesions are divided fairly easily and carry a very low risk. Thick, leathery adhesions carry a somewhat greater risk but can still be divided safely. When adhesions are so severe that structures become fused, it becomes very difficult to divide these structures without some risk of entering one or the other of the fused organs. While injury to an internal organ is rare in the hands of an experienced laparoscopic surgeon, it is possible, and needs to be considered when weighing the risks of surgery. When injury to organs occurs, it can most frequently be dealt with by repairing the injured organ using laparoscopic techniques. In rare cases it can require additional surgery, and can require that an open operation be performed. Injury to the intestines can cause leakage of intestinal fluid, which contains bacteria, which can raise the risk of infection. Finally, because laparoscopic lysis is by its very nature a surgery it inevitably has the potential to cause more adhesions or the reformation of old adhesions if not performed with the utmost of care. This all underscores the need to seek out surgeons experienced with this procedure.

### **Prevention:**

The most important factor in the treatment of adhesions is prevention. A number of new techniques and devices are being developed to reduce the amount of adhesions that occur following surgery. Many new laparoscopic surgical techniques are replacing standard surgical alternatives with the intent of lowering the amount of adhesions seen in the future. Even very large operations, which have been difficult to perform laparoscopically, can now be carried out using Hand Assisted Laparoscopic techniques. (See [www.dexteritysurgical.com](http://www.dexteritysurgical.com) for more information) This significantly reduces the size of the incision and decreases the amount of adhesions from larger operations.

In addition to using microsurgical or laparoscopic techniques, prevention of infection is essential to the prevention of adhesions. Thus general antibiotics should be administered prior to surgery. In addition, surgeons take a number of other steps to try and prevent the formation of adhesions. Surgeons limit any unnecessary handling of the organs, avoid using dry sponges, make sure to constantly irrigate the cavity during a surgical procedure, avoid unnecessary damage to organs, tissues or blood vessels, and use the finest size suture thread appropriate to the surgery.

Also there are currently many products on the market which have been created to prevent the contact of two separate raw tissue surfaces as they heal, thus hindering the formation of adhesions.

These include barriers in membrane and liquid/gel form. One of these products is known as Seprafilm. In studies it has been shown to reduce the risk of first adhesive small bowel obstruction up to 47%. Seprafilm is indicated for the reduction of post surgical adhesions in patients undergoing abdominal or pelvic laparotomy. It is not labeled for use in preventing small bowel obstructions in colorectal surgeries. Another product is known as Gynecare Interceed. Studies with the Gynecare Interceed barrier demonstrate that the barrier enhances good surgical technique and its use reduces adhesion formation up to 50% more than good technique alone. These two products are the only two products currently approved by the FDA to aid adhesion prevention in post- surgical situations. Another product is Adhibit. There are also studies which confirm the ability of this product to reduce formations up to 50%, however, because this product is delivered in a sprayable form it can provide adhesion protection even in laparoscopic surgeries. Adhibit is currently approved in Europe to reduce adhesion formation in pediatric cases of cardiac surgery. Most of these products are short lived. They are biodegradable and are absorbed by the body a couple of days after the surgery. Also while there is little evidence yet to support their use, some surgeons use saline (salt water), heparin (blood thinning medication), steroids or fibrinolytics ( substances that effect clot formation), and antihistamines to reduce adhesion formation.

### **Statistics:**

Ten to twenty percent of women of child bearing age in America, about 5.5 million suffer from some degree of endometriosis . Nearly one out of every seven American women between the ages of 18 and 50 suffer from chronic pelvic pain. Of these an estimated thirty eight percent have adhesions. Studies have also linked adhesions to the cause of sixty to seventy percent of small bowel obstructions in adults. Those women suffering from pelvic pain for reasons including but not limited to adhesions account for twenty percent of all laparoscopic surgeries and twelve to sixteen percent of all hysterectomies. Though studies vary wildly it is generally agreed upon that of those patients who have had abdominal surgery, sixty seven (Weibel and Majno, 1973) to ninety three percent (Menziess and Ellis, 1990) will develop some form of post operative adhesion within six months and of those patients who have had pelvic surgery fifty five to one hundred percent will develop some form of post operative adhesion within six months of surgery (Ellis, 1997) In fact nearly half of all female infertility is attributed to adhesions. Abdominal adhesions also occur in 10.4 percent of people who have never had surgery. Of these, it has been shown that only around thirty percent of adhesions patients are symptomatic. Of these forty nine to seventy four percent have small bowel obstruction, fifteen to twenty percent have problems with infertility and twenty to fifty percent have chronic pelvic pain. Studies have found that a patient undergoing pelvic or abdominal surgery will be readmitted on average 1.9 times over the ten years following surgery for a problem related to adhesions (Lower et al., 2000). There are around 300,000 hospital admissions in the U.S. every year for patients due to adhesions. Over the last five years, the number of people in the U.S. that have died with a diagnosis of intestinal obstruction to adhesions has varied between 2100 and 2500 death per year. Woman form 60% of these deaths. In 2001 alone, there were 67,000 discharges with the primary diagnosis being adhesion related obstruction. The average time of hospitalization was 9.8 days with the average charge being \$32,000 which comes to a total economical cost of \$2.15 Billion. Adhesions tend to gain more prominence with age. Nearly 30% of adhesion related obstruction occurred in the 45- 64 age range and 53% occurred in the 65+ age range. The greatest risk of death (10%) occurred after age 85.



## **Introduction**

### **Diagnosing:**

One of the most difficult steps in the treatment of adhesions formation is accurately diagnosing the presence of adhesions and their location. One problem is that adhesions have no unique symptoms of their own . From person to person the symptoms can differ. They can range from pain to discomfort to inflammation and they can cause any number of indirect symptoms such as anxiety, depression, problems with conception, trouble eating, and decreased immune function. Another problem is that there is currently no non invasive test which will clearly identify the presence of adhesions.

Diagnosis of patients with adhesions begins with a careful review of their medical history, correlating their symptoms with other activities , looking at previous medical evaluations and previous attempts at correcting their symptoms. A physical examination by a physician, who is knowledgeable of adhesion induced problems is important. It may also be necessary to examine abdominal scars for possible signs of hernia, poor healing or other problems. Use and review of old x-rays, CAT scans, and ultrasounds can also be helpful. For women, a gynecologic examination may be necessary, particularly when symptoms relate to their gynecologic system. The results of these tests and examinations can only suggest the presence of adhesions. Currently, there is no one x-ray or other non invasive test that will clearly identify adhesions in the body.

Diagnostic laparoscopy or needleoscopy can be performed to detect adhesions. Laparoscopy is a form of surgery where a small tube is used to enter the abdomen. A telescope, referred to as a laparoscope, is then placed through this tube and the internal abdomen examined. Needleoscopy is a form of laparoscopy that uses very small instruments which are about the size of a needle. Diagnostic laparoscopy or needleoscopy allow the physician to diagnose adhesions with very high accuracy. The two procedures do, however, have one big down side. Since these procedures are surgical in nature, they themselves can cause adhesions. Therefore the use of these procedures to diagnose a patient for adhesions, whether or not he or she actually has adhesions, risks the forming of adhesions in the patient post surgery.

Not only is a non invasive diagnostic system needed to diagnose possible adhesion in people with symptoms, but it is needed to diagnose adhesions for people without symptoms undergoing any type of laparoscopy. In all abdominal laparoscopic procedures an incision must be made through which a trocar or gas insufflation needle is passed. The incision usually takes place about the umbilicus. After the incision is made the abdomen is filled with gas, typically carbon dioxide, which expands the abdomen allowing the physician to view the innards of the abdomen and possible adhesions in a clear manner. To make sure that they do not cut underlying organs when making the initial incision, physicians pull up the top layer of skin with their hand as they cut. Yet it is quite possible that an adhesion exists between internal organs and the abdominal wall itself, unknown to the doctor and patient . This would make it impossible to properly pull up the wall of the abdomen giving clearance to cut since the organ itself is stuck to the abdomen wall. In such a case if a physician were to incise the patient they would cut through the organ along with the wall and cause massive bleeding and possible future trauma. Therefore using the only method available to them, physicians feel for adhesions directly under the abdomen wall by hand. This process of feeling is not entirely effective and results in incisions directly into underlying

adhesions. Therefore there is a great need to have effective non invasive and diagnostic tools both to diagnose symptomatic patients and patients undergoing any type of laparoscopy, regardless of their symptoms.

To answer these problems, many researchers have conducted experiments testing the ability of ultrasound to diagnose adhesions in the body. Most of these studies center around one type of adhesion formation, where there is an adhesions attaching the bowels to the overlying anterior abdominal wall. In these studies, the physicians analyzed the motility of the viscera (intestines or omentum), as seen on ultrasound, as a possible marker for indicating the presence of such adhesions. Kodama et al tested five patients with little risk of adhesion formation and no previous history of abdominal surgery They showed that all five patients with no previous history of surgical operation had ultrasound-visualized movement of the underlying viscera (visceral slide) of at least 2.5 cm during forced and exaggerated respiration. They also tested 13 patients at risk for adhesions formation and showed that of the seven out of thirteen that had visceral slides less than 1 cm, all had adhesions beneath the scar. Caprini et al studied 30 patients with previous abdominal surgery, successfully identifying all 4 patients with infraumbilical adhesions while excluding the 26 normal patients, using the same cutoff. In contrast, Uberoi et al, using visceral slide thresholds of 1.2 to 1.5 cm in all 4 abdominal quadrants, studied 48 patients undergoing abdominal surgery. They reported a sensitivity of 21% and specificity of 94%, and expressed concern for the large number of false positives they encountered. It is however worth noting that the Caprini et al study and the Uberoi et al study observed visceral slide during spontaneous respirations, rather than exaggerated respiration. Following these studies and understanding the benefits of using exaggerated respiration to diagnose adhesions, Tu et al conducted their own study testing 60 women for adhesion formation in the umbilical area. Firstly, testing a number of cut offs, they found that 1 cm offered the best cut off between a normal visceral slide and a hindered visceral slide due to adhesions. Secondly they found that the positive predictive value for people with adhesion risk factors was 73% at this cut off and the negative predictive value for the same group was 90% at this cut off. Also they found the positive and negative predictive value for their not at risk group to be 100%.

The results of studies measuring visceral slides under ultrasound using exaggerated respiration are very promising. Yet there are still weaknesses in the predictive power of these procedures, especially with regard to positive predictive values. For such procedures to be successfully implemented into clinical medicine and offer non invasive methods to diagnosing adhesions, they must first be able to offer higher percentage predictive values. We propose a model of an external abdominal vacuum system which will increase the accuracy and predictive values of measuring visceral slides under ultrasound using exaggerated respiration. Thus we propose a system, which combined with ultrasound, will increase the accuracy of properly diagnosing the presence of and location of adhesions in patients.

## **Materials and Methods**

### **Choosing a Method:**

To answer the need for a non invasive method of diagnosing adhesions we considered three methods. The first method was transillumination. Transillumination is a method where a bright light is shown through a surface of the body, allowing a physician to diagnose certain physical abnormalities such as hydrocephalus in an infant brain, lesions or cysts on the breast of a woman, and pneumothorax in an infant chest. Studying transillumination we determined that although it is possible to transilluminate through the chest of an infant it is not possible to transilluminate from the dorsal side to the ventral side of the abdomen of an adult. Instead we considered a system where the outer surface of the abdomen was pulled up in certain sections at a time and light was transilluminated perpendicularly through the pulled up section and parallel to the surface of the abdomen.

The second method we looked at involved laying a piece of material on the patient's abdomen and running a small current from the dorsal side of the abdomen to ventral side of the abdomen and through the material. The material chosen would need to have the ability to change color in the places where the current was passed through it. For this method to work, we hypothesized that the internal resistance of the abdominal fluid and the internal resistance of the adhesion would be different. Therefore, the current would run through the less resistant of the two. If no adhesion was present then the material would be unvarying in color. If an adhesion was present then there would be spots of discoloration on the material to indicate adhesions.

The third method we looked at involved moving the body and using ultrasound to diagnose the presence of adhesions. To do this the ultrasound would be used to measure the movements of the internal organs and a physician could predict the presence of an adhesion from the loss of movement in a certain area. Upon researching the idea, we found that this third method had already been experimentally tried. The results of these trials proved promising but not yet entirely successful. Looking at this third method in more depth we determined that we could create a mechanical device which would increase the accuracy of diagnosing adhesions using ultrasound, therefore we chose to pursue this third method.

### **The Abdominal Vacuum System:**

The main purpose of the device was to allow for the use of ultrasound and at the same time to create a vacuum on the outside of the abdomen to pull up the outer surface of the abdominal wall and create more space in the abdominal cavity. To create this vacuum we constructed a closed system created out of a clear, plastic, rectangular container. The container would have one open side which would be placed on the outer surface of the abdomen to form a closed system. A vacuum would then be run through a hole in the top of the container creating a difference in pressure in the container which would pull up the surface of the abdomen.

Since our device had to operate in conjunction with ultrasound, the device had to allow the ultrasound transducer to come in contact with the abdominal surface exposed to the vacuum. In other words the mechanical device had to allow for the abdominal transducer to be placed in the vacuum. To do this a hole needed to be made separate from the hole for the vacuum through which the transducer would be

inserted into the container. The hole then needed to be sealed to contain the vacuum. Since the transducer needed to operate within the vacuum and it is traditionally moved by hand, we needed to create a system where we could move the transducer from the outside of the container.

### **Transducer:**

The ultrasound transducer which we modeled our device around was a Phillips manufactured abdominal convex transducer. The model was C5-2 and it operated between five and two mega hertz. The Phillips transducer was provided to us by North American Imaging Inc. free of charge. This Phillips transducer runs on both the Phillips HDI5000 and HDI3000 ultrasound systems. For the purposes of further research these two operating systems can be rented from Medcorp. for \$300 a month. The Phillips transducer we received is composed of three segments, which are not separable. One segment is the transducer itself (Please see Fig 1), which is five inches tall and three by one inches wide at the bottom. The second segment is a long extension of cord, five feet long and a half inch in diameter, connecting the transducer to a control box. Directly after the top of transducer the cord is stiff for one and half inches. The third segment is the control box (Please see Fig 2). The control box is two inches tall and five by four inches wide.

### **First Model:**

Before we received the Phillips transducer we developed a model using a clear, plastic, polyethylene container through which the vacuum could be run to the surface of the abdomen. This original container had only one hole for the vacuum. Because we did not know the dimensions of the transducer and the cord we could not make an appropriate second hole for the transducer. The dimensions of this container were three inches tall, six by eight inches wide, and one eighth inch thick. It was important that the container be a quarter inch thick so that the polyethylene did not collapse inward due to the pressure of the vacuum. This effect would cause there to be no upward force on the surface of the abdomen. After receiving the Phillips transducer we realized that the container was not tall enough to house the transducer, therefore we needed develop a new model.

### **Second Model:**

We developed a new model using a new clear, polyethylene container which was nine inches tall, eight inches in diameter, and one eighth inch thick. This new container had a small, quarter inch hole for vacuum attachment. It also had a second hole four inches in diameter through which we could fit the abdominal transducer. We set up a system to move the transducer in the vacuum from the outside of the container using a U-bent piece of steel which was inserted into the container through two holes, each a quarter in diameter. Velcro was glued to the ends of the U-bent steel piece. Velcro was also glued to the sides of the transducer allowing us to move the transducer within the vacuum by moving the curve of the U-bent steel from the outside. Inserting and sealing the transducer in the container proved to be quite a difficult task. Sealing the transducer in the container required that the four inch diameter hole be converted to a half an inch diameter hole which would seal around the cord. Typically, sealing a hole around a cord in this type of situation could be done with an inverted lip seal, however, because of the control box at the other end of the cord the cord could not be run through the lip seal. Therefore, a seal had to be created which could open and close around the cord. In the meantime we used duct tape to seal the holes in the container.

### **Third model:**

In our next model we used the same cylindrical polyethylene container, but this time we switched the control which moved the transducer from the U-bent steel, inserted through the side, to a long, straight steel rod inserted through the top. We found this method gave much better control. The rod was five inches in diameter, as well as the hole, and the rod was seven inches long. Again it had Velcro glued to it at the bottom, which attached to the Velcro glued to the sides of the transducer. In this model the holes were again sealed with duct tape.

### **Fourth Model:**

We then created a fourth model. In this model we used a new clear polyethylene container. To minimize the volume of the container and still allow the container to house the transducer we created a container which was seven and a half inches tall and six by six inches wide. The container was again one eighth inch thick. The container again had a quarter inch hole for the vacuum. On the top surface of the container, around the hole, we attached a piece of black, cylindrical rubber to form as a connection site to vacuum hose. We created a four inch diameter hole through which the transducer could be placed. In forming the four inch diameter hole we accidentally created a few cracks in the top surface of the container. The cracks were temporarily sealed using clear tape.

To seal the four inch hole we used a specially constructed rubber stopper. The rubber stopper needed to be slightly over four inches in diameter with lips that reached out another quarter of an inch. The stopper was cut halfway down the center and at its center a one half inch hole was drilled so the cord could run through the stopper. (Please see Fig 3) First the transducer was placed into the hole, and then the stopper was placed around the cord and into the hole by opening the cut in the stopper and sliding the cord to center hole in the stopper. The stopper was then closed. Because the stopper was slightly larger than the hole it was able to form a good seal around the cord.

Again we used a metal rod inserted through the top of the container, however this time the rod was one quarter inch in diameter. The rod was also longer, this time the rod was one and a half feet long and had a screw driver handle at the end for grip. Again Velcro was glued to the bottom of the rod which could attach to the Velcro on the side of the transducer. (Please see Fig 4). To seal the hole of the control rod proved difficult. Because the transducer needed to move within the container, the control rod also needed the ability to move. Due to this need the control rod needed a seal which could provide the control rod with the freedom of pivoting in all directions. Temporarily we used regular clear tape which was effective in providing a seal to the hole for the control rod and still allowed the rod some freedom to pivot. The seal we plan to implement is a seal with a swivel joint similar to the ones seen in shower heads.

## **Results**

### **Fifth Model**

Using what we learned from the physical and ergonomic problems of our earlier models we developed a fifth model. In this model we chose a new, clear, lexan container. The lexan container would be created using vacuum forming. The lexan container would be eight inches high, six by eight inches wide and one eighth inch thick. (Please see CAD Fig. 7-12). To give physicians a clearer view of the location of the ultrasound in the container we moved the vacuum hole and the cord hole for the transducer to the lower part of the sides of the container. The vacuum hole and the cord whole can be separated with two different seal or together in the same seal. In the CAD drawings we can see the two holes are separated. If, however, we use the same large cord whole for both we can design a special seal which will allow us to run a cord and a vacuum through the same area under the same seal. (Please see Fig 5). Therefore the only hole on the top of the container was the control rod hole. Because we found it was ergonomically easier to control the transducer from the top of the container as opposed to the sides we left this hole on the top of the container. We did, however, move this hole to the edge of the top surface of the container, giving the physician more room to clearly see the location of the transducer on the outer abdominal surface. We also added an appropriate seal for this control rod which would seal the hole effectively and at the same time give the rod leeway to pivot. (Please see Fig 6) This seal is three quarter inches in diameter at the top and has a one quarter inch whole for the rod to go through. Yet it is unique in the fact that it spread out radially to one inch in diameter as we go to the bottom surface. The bottom surface is also sealed except for a one quarter hole allowing the rod to pas through. Finally the bottom surface is sealed with very flexible rubber so the rod has freedom to pivot and the hole remains sealed. To fit in this seal we raised the diameter of our hole to one inch in diameter on the top of our device. The vacuum hole remained at one quarter in diameter and the cord hole at three inches in diameter. In addition, to improve the ergonomic nature of our model, we created a shallow curve on the open surface of the container to more accurately fit the shape of the human abdomen when the open surface is pressed up against the outer surface of the human abdomen during vacuum suction. This curve, on the open surface, had a radius of curvature of twenty four inches.

Trying to create the fifth model above we learned that it is extremely hard to stretch lexan to the distances we wanted (six and eight inches) using vacuum forming. So we replaced lexan in our model with glycol-modified polyethylene terephthalate or PETG for short. In vacuum forming this material a complication arose where although the PETG itself was clear the vacuum formed product composed of PETG was not. Instead it was cloudy. To allow the physician to see inside we then created windows all around our device. After cutting away the extra plastic from the vacuum forming process, the device is the same as the CAD model in shape and dimensions except that it uses the one seal system for both the vacuum and the cord.

### **Vacuum Testing**

Simultaneous to our construction of the various models of our abdominal vacuum system we tested two main aspects of the device. The first aspect was the ability of our system to create a successful vacuum without leaking. Testing our third and forth models on the human abdomen of a patient at low risk of adhesion formations, with the aid of a vacuum cleaner, we found that both models were able to successfully create a vacuum within the container. This was seen by a visible extension in the abdomen of about one to one and a half inches in this low risk patient. It is worth noting that the patient had an average amount of body fat.

The second aspect which we tested was whether or not, and to what extent, our vacuum system would cause discomfort to the patient upon pulling up their abdomen. To answer this question, the patient in the above tests was asked to describe the level of discomfort during the experiment. It was then promising to note that the patient described no discomfort in any of the experiments.

## Discussion

A non invasive accurate diagnostic system to diagnose organ adhesions is highly needed. Not only is such a system needed to diagnose possible adhesion in people with symptoms, but it is needed to diagnose adhesions for people without symptoms undergoing any type of laparoscopy. No method currently is in use for inexpensive and non invasive identification of abdominal adhesions before laparoscopy. Studies by Kodama et al., Caprini et al, and Tu et al suggest that measuring visceral slides under ultrasound using exaggerated respiration may prove very promising in diagnosing adhesions non invasively. Ultrasound is readily available to gynecologists and surgeons, and is commonly used to guide percutaneous procedures. Yet there are still weaknesses in the predictive power of these procedures. For such procedures to be successfully implemented into clinical medicine and offer non invasive methods to diagnosing adhesions, they must first be able to offer higher percentage predictive values. We propose that our model of an external abdominal vacuum system will increase the accuracy and predictive values of measuring visceral slides under ultrasound using exaggerated respiration.

In the above studies and under normal ultrasound conditions, all of the internal organs remain in close proximity to one another, scrunched up due to the limited volume of the abdominal cavity, even during exaggerated respiration of a patient with no internal adhesions. Thus typically the visceral slides are very low, on the order of one to three centimeters. For patients with internal adhesions, the organs may be slightly hindered, but the organs still do move a bit relative to each other causing small visceral slides which are not much less than those experienced by patients with no internal adhesions. Thus it is difficult to get a high percentage of accuracy when diagnosing the presence of an adhesion . Our abdominal vacuum system will lower organ movement in the area of an adhesion and raise it in areas unconnected by adhesions. This will provide decreased visceral slides in the presence of an adhesion and increased visceral slides in an area not containing an adhesion. Then using ultrasound, physicians will be able to accurately diagnose the presence of and location of adhesions by measuring the new visceral slides. For our system to work the patient is first put in the traditional Trendelenburg position. In this position the head is inclined down and the knees up. While the patient is in this position their organs fall towards the diaphragm and to the back of abdominal cavity. The external abdominal vacuum system will then slightly lift the upper wall of the abdomen out causing a separation between the internal organs and the inner wall of the abdominal cavity. If there are any adhesions between internal organs and the abdominal wall they will be stretched slightly outwards. Stretching these adhesions in the tensile direction (outward) will limit the ability of the adhesions as well as any attached organs to move in the plane of the body (up and down and side to side). Thus these areas containing adhesions will have lower visceral slides. On the other hand, since we have expanded the abdominal cavity using the abdominal vacuum system, the rest of the organs will be spaced by fluid in between and have a greater ability to move. Thus these areas with no adhesion formation will have increased visceral slides.

As an addendum to our system, a physician must only tilt the table a little in every direction to increase the visceral slides in non adhesion areas. If the vacuum is working the adhesion and connected organs will still remain immobile and not move relative to the umbilicus which is the reference on the ultrasound. Since we have created an excess of space in the abdominal cavity using our abdominal vacuum system, the organs will be free to move with the tilt of the table even where they would not have moved under exaggerated respiration.



The presence of any adhesion connecting the internal organs to the abdominal wall will effect our ability to pull out the abdominal wall. In cases of no adhesion formation, we will be able to pull the wall out more for a given pressure difference than for cases with adhesion formation. Identically for cases with more elastic adhesions (earlier stage) we will be able to pull out the wall more than for case with more fibrous adhesions (later stage) . Thus the mere measurement of the extension of the abdomen under different pressure differentials can offer a means of indicating the presence of and form (early or late stage) of an adhesion. This combined with the visceral slide procedure will further increase the accuracy of non invasively diagnosing abdominal adhesions.

There is one novelty to the vacuum abdominal approach. For patients with greater amounts of body fat pulling up the outside of the stomach does not necessarily assure movement of the inner abdominal cavity. We may simply be sucking up fat. This problem, however, is not unique to us. The same problem arises when physicians must lift the patient's upper abdominal wall by hand before making their initial incision. Their solution is that they simply apply more force. For our product to work on patients with greater amounts of fat we too must use our system under a greater force or pressure differential. To do so we need only increase the pull of the vacuum. Thus it becomes important to find what level of pressure differential is appropriate for patients with different amounts of fat. Directly related to this, to use the measurement of the extension of the abdomen to indicate the presence of and form of adhesions we must keep in mind the amount of body fat on the patient. Patient's with more body fat will give more extension under equal differentials in pressure. Thus this method can still be used, but it is important to experimentally determine and have references for given extensions relative to different fat amounts.

There is a lot of further research which must be done into these methods, but we see that there are also many different ways that our vacuum abdominal system can be adapted along with ultrasound imaging to determine the presence of, location of, and forms of adhesions non invasively.


## References

1. Kodama I, Loiacono LA, Sigel B, Machi J, Golub RM, Parsons RE et al. Ultrasound Detection of Viscera Slide as an Indicator of Abdominal Wall Adhesions. *J. Clin Ultrasound* 1992;20:375-80
2. Caprini JA, Arcelus JA, Swanson J, Coats R, Hoffman K, Brosnan JJ, et al. The Ultrasonic Localization of Abdominal Wall Adhesions. *Surg Endosc* 1995;9:283-5
3. Uberoi R, D'Costa H, Brown C, Dubbins P. Visceral Slide for Intraperitoneal Adhesions. A Prospective Study in 48 Patients with Surgical Correlateion. *J Clin Ultrasound*. 1995;23:363-6
4. Frank F. TU, Georgine M. Lamvu, Katherine E. Hartmann, John F. Steege. Preoperative Ultrasound to Predict Infraumbilical Adhesions: A Study of Diagnostic Accuracy. *Am J Obstet Gynecol*. 2005;192(1):74-9.
5. Eslick, Joanne." Adhesions." [Online] Available <http://www.bombeach.com>, revised 2004.
6. Gynecare Worldwide. " Adhesions -What Can Cause Adhesions?" [Online] Available [http://www.genecare.com/bgdisplay.jhtml?itemname=adhesions\\_pelvic\\_pain\\_causes](http://www.genecare.com/bgdisplay.jhtml?itemname=adhesions_pelvic_pain_causes). Downloaded 01/8/2006.
7. Gynecare Worldwide. " Adhesions-How Are Adhesions Diagnosed?" [Online] Available [http://www.genecare.com/bgdisplay.jhtml?itemname=adhesions\\_pelvic\\_pain\\_diagnosing](http://www.genecare.com/bgdisplay.jhtml?itemname=adhesions_pelvic_pain_diagnosing). Downloaded 01/8/2006 .
8. Gynecare Worldwide. " Adhesions- What Women Should Know About Prevention And Treatment." [Online] Available [http://www.genecare.com/bgdisplay.jhtml?itemname=adhesions\\_pelvic\\_pain\\_information](http://www.genecare.com/bgdisplay.jhtml?itemname=adhesions_pelvic_pain_information). Downloaded 01/8/2006.
9. Gynecare Worldwide. " Adhesions- Questions Patients Should Ask Their Doctor Prior To Surgery." [Online] Available <http://www.RESOLVE.org>.
10. "Help for Endometriosis: Learn About Symptoms and Treatment." [Online] Available <http://sharedjourney.com/define/endometriosis.html>. Downloaded 01/8/2006.
11. Hardin, Eugene. " Adhesions and After Surgery." [Online] Available <http://www.emedicinehealth.com/fulltext/13796.htm>. Downloaded 01/8/2006.
12. "Adhesions- Health and medical information for consumers, from the Victorian government." [Online] Available <http://www.betterhealth.vic.gov.au/bhcv2/bhcarticles.nfs/pages/Adhesions?Open.> n. 1/10/2006.


13. Wurn , Belinda (Clear Passage Therapies, inc..) “Increasing Natural Pregnancy Rates.” [Online] Available [http://www.clearpassage.com/increasing\\_Natural\\_Pregnancy.htm](http://www.clearpassage.com/increasing_Natural_Pregnancy.htm). 1/8/2006.
14. Wurn, Belinda “Treating Female Infertility and Improving IVFF Pregnancy Rates With a Manual Physical therapy Technique.”[Online] Available Medscape General Medicine, from WEBMED, Posted 06/18/2004.
15. National Digestive Diseases Information Clearinghouse “ Intestinal Adhesions.” NIH Publication No.04-5037, February 2004,[Online] Available.
16. Wiseman, David “Adhesion Related Disorder {ARD} Raising World Wide Awareness and Education .“ [Online] Available <http://www.adhesionrelateddisorder.com/> Downloaded 01/9/2006
17. Wiseman, David “A Patient’s Guide To Adhesions & Related Pain” [Online] Available [http://www.adhesions.org/ptguide\\_print.htm](http://www.adhesions.org/ptguide_print.htm) . Downloaded 01/9/2006. <http://www.adhesions.org> <http://obgyn.net/women/bios/wisemann.htm>
18. International Adhesion Society “What’s New at the International Adhesions Society ( November 2005).” [ Online] Available <http://www.adhesions.org/whatsnew.htm> . Downloaded 01/08/2006.
19. International Adhesions Society “Adhesion FAQs.” [ Online] Available <http://www.adhesionsorg/faqs.htm>. Downloaded 01/09/2006.
20. International Adhesions society “ Adhesion Related Disease- Adhesion Related Deaths” [Online] Available <http://www.adhesions.org> . 09/23/2003
21. “Female Health Made Simple –Endometriosis” [ Online] Available [http://www.femalehealthmadesimple.com/File\\_thirteenFinal.html](http://www.femalehealthmadesimple.com/File_thirteenFinal.html) . Downloaded 01/09/2006.
22. “Female Health Made Simple- Adhesions.” [Online] Available <http://www.femalehealthmadesimple.com/Adhesions.html> . Downloaded 01/09/2006.
23. Ferland, R . “Evaluation of a Sprayable Polyethylene Glycol Adhesion Barrier in a Procine Efficacy Model” [Online] Available <http://humrep.oxfordjournals.org/cgi/content/full/16/12/2718>. Downloaded 01/08/2006.
24. Lower, A.M. “ Adhesion-Related Readmission Following Gynaecological laparoscopy or Laparotomy in Scotland: an epidemiological study of 24,046 patients”, Human Reproduction vol. 19 no. 8 , 2004 p1877-1885. Originally Published June 3, 2004 [Online]. Available ISSN 1460-2350 Print ISSN 0268-1161. <http://humrep.oxfordjournals.org/cgi/contents/full/19/8/1877>.
25. Daiter, Eric “Reduction of Postoperative Adhesions (Scar)” [Online] Available <http://www.drdaiter.com/hyst3.html>. Downloaded 01/08/2006.
26. Samudovsky, Kathy “Prisoners of Post-Surgical Pain.” [Online] Available <http://www.post-gazette.com/pg/04188/342138.stm> . Downloaded 01/08/2006.
27. Luijendijk , R. W. “Foreign Material in Postoperative Adhesions.” Annals of Surgery. 223(3) : 242-2488, March 1996. [Online] Available <http://www.annalsofsurgery.com/pt/re/annos/abstract.00000658-199603000-00003.htm;jsessionid=...> Downloaded 01/08/2006.

28. "A Patients Guide-Definition of Endometriosis" [Online] Available <http://www.valis.com/andi/endo/definition.html>. Downloaded 01/08/2006.
29. "A glossary of Terms Related to Circumcision and the Genital Organs" [Online]
30. Wiseman, David "September is Adhesion Awareness Month" [Online] Available <http://www.medicalnewstoday.com/medicalnews.phpnewsid=30123> Downloaded 01/09/2006.
31. "Diagnostic Laparoscopy" [Online] Available <http://www.monlezun.com/diaglap.htm> . Download 01/08/2006.
32. "A-Z health guide from WebMD: Medical tests Laparoscopy" [Online] Available [http://www.webmd.com/hw/digestive\\_problems/hw231905.asp](http://www.webmd.com/hw/digestive_problems/hw231905.asp) . Downloaded 01/08/2006.
33. Wurn, Lawrence "Increasing Orgasm and Decreasing Dyspareunia by a manual Physical Therapy Technique." [Online] Available <http://www.medscape.com/viewarticle/4939989> . Posted 12/14/2004, Download 01/08/2006.
34. "Adhesions- What are they and can I prevent them?" [Online] Available [http://www.hystersisters.com/vb2/article\\_157375.htm](http://www.hystersisters.com/vb2/article_157375.htm) . Download 01/08/2006.
35. "Uterine Suspension After Endometriosis Surgery to Help prevent Adhesion Formatin." [Online] Available [http://www.inletmedical.com/pelvic\\_adhesion\\_prevention.asp](http://www.inletmedical.com/pelvic_adhesion_prevention.asp) . Download 01/08/2006.
36. "Adhesions" [Online] Available <http://www.doctornet.com/ttopicsh/Adhesions.asp> Download 01/08/2006.
37. Williams, Carol "Husband hopeful for success in German adhesion removal procedure" [Online] Available (American Adhesions Support Group) <http://www.bombobeach.com> .
38. Al-Musawi, D. "Adhesion Prevention : State of The Art" Gynaecological Endoscopy vol. 10(2), page 123-130, April 2001.
39. "technology for Surgical Adhesions" [Online] Available <http://www.angiotech.com/?seeknamed=surgical> adhesion . Download 1/8/06.
40. "The effects of Adhesions" [Online] Available <http://www.angiotech.com/?seek=75> . Download 1/8/06.
41. "A Closer Look At Surgical Adhesions" [Online] Available <http://www.angiotech.com/?seek=75> . Download 1/8/06.
42. "SprayGel Adhesion Barrier" [Online]
43. Demco, Larry "Adhesions" [Online] Available [http://www.obgyn.net/displaytranscript.asp?page=/avtranscripts/wce2klondon\\_diamond](http://www.obgyn.net/displaytranscript.asp?page=/avtranscripts/wce2klondon_diamond) .
44. "Adhesion-Related Hospital Readmissions After Abdominal and Pelvic Surgery: a Retrospective Cohort Study." [Online] Available [http://www.ncbi.nlm.nih.gov/entrez/query.fcgi?cmd=Retrieve&db=PubMed&list\\_uids..](http://www.ncbi.nlm.nih.gov/entrez/query.fcgi?cmd=Retrieve&db=PubMed&list_uids..) Download 01/09/2006.

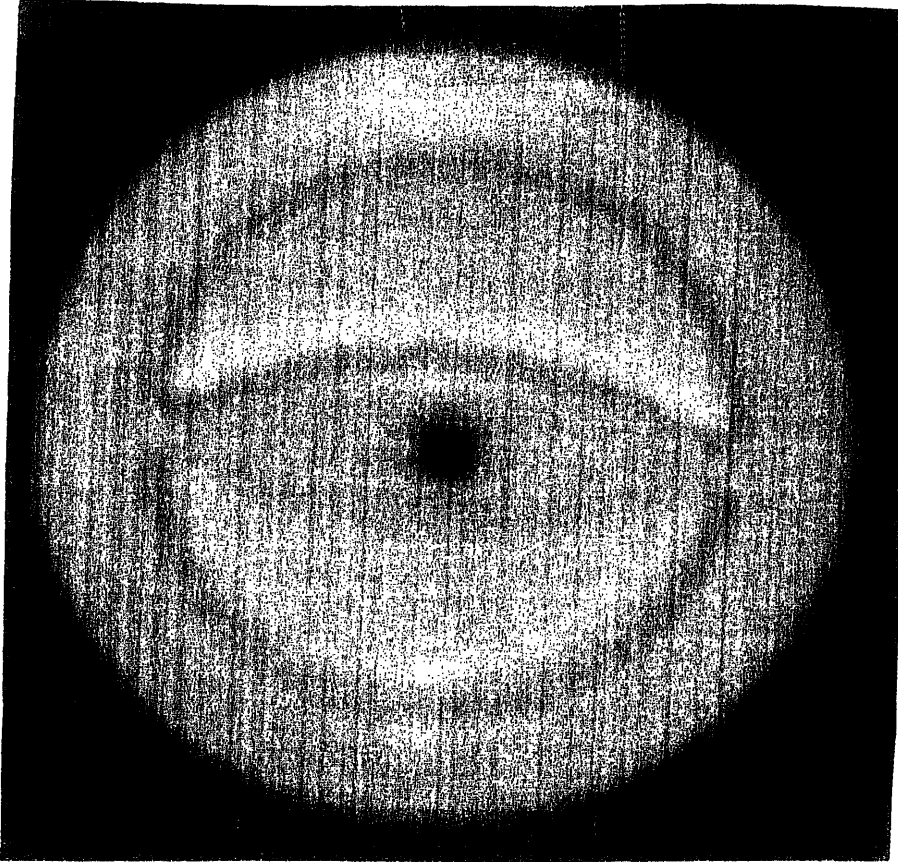
45. "The Effect of the Degree of Histologic Inflammation on Gallbladder Perforation During Laparoscopic Cholecystectomy" Journal of laparoendoscopic & Advanced Surgical Techniques vol. 15, No 2 page 130-134 [Online] Available <http://www.liebertonline.com/doi/abs/10.1089/lap.2005.15.130> Download 1/8/06




**Fig. 1) Convex abdominal Transducer**



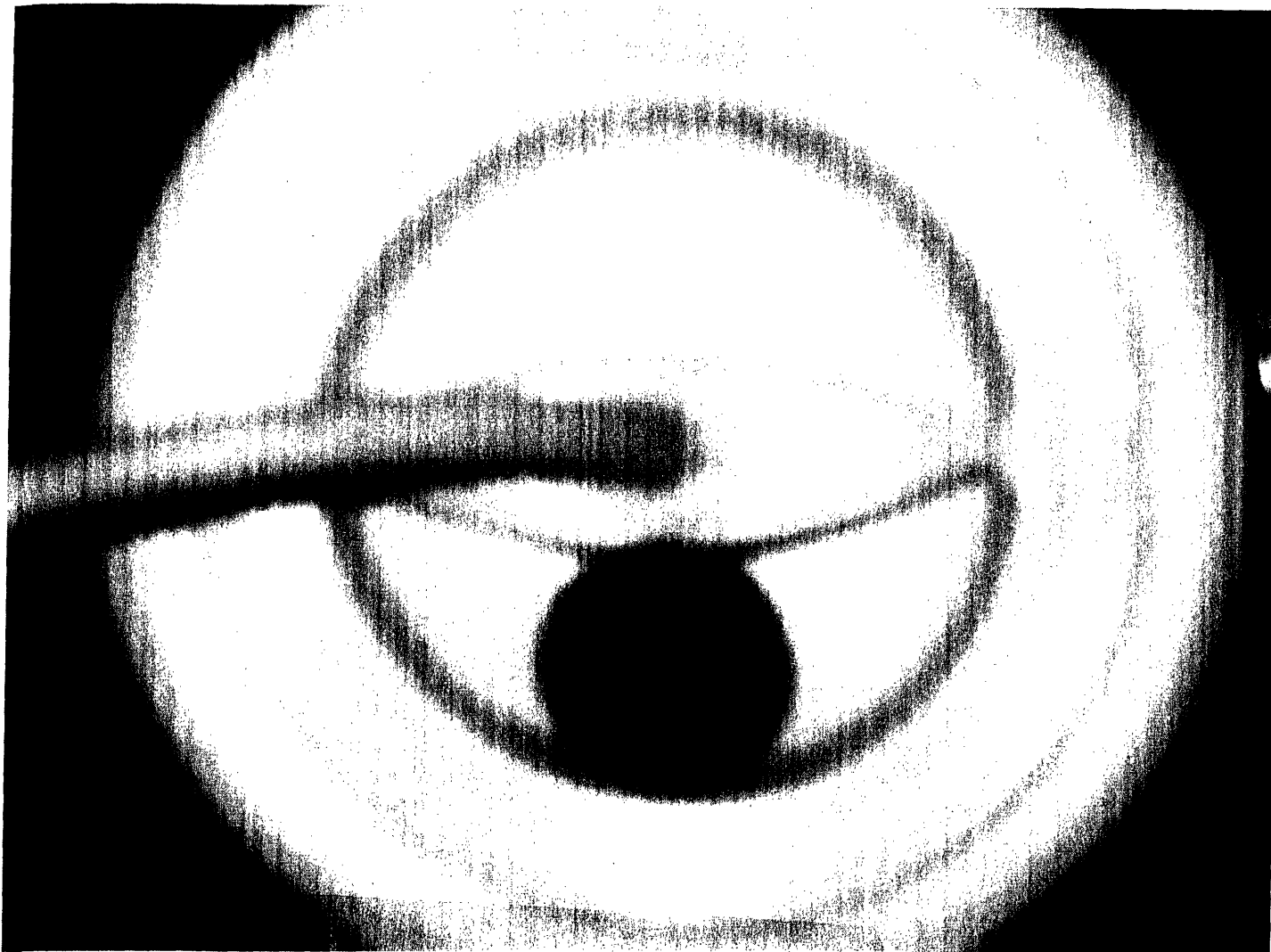
**Fig. 2) Control Box**



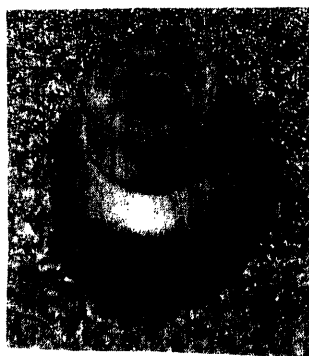**Fig. 3) Stopper**



**Fig. 4) Control Rod**




**Fig. 5) Duo Vacuum Cord Seal**

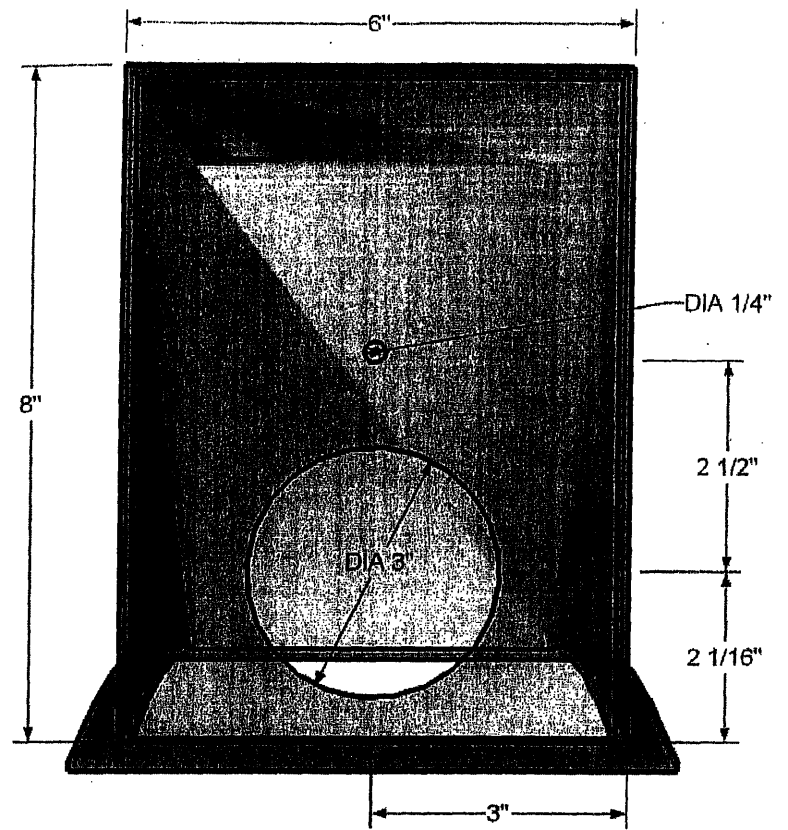


**Fig. 6) Control Rod Seal**







**Fig. 7) Isometric View of Container**




**Fig. 8) Front Side View of Container**




**Fig. 9) Bottom Side View of Container**




**Fig. 10) Top Side View of Container**



**Fig. 11) Side View of Container**



**Fig. 12) Back side view of Container**



**Fig. 13) Fourth Model**