

MIT Open Access Articles

*Ultra-High-Resolution Optical Coherence  
Tomographic Findings in Commotio Retinae*

The MIT Faculty has made this article openly available. **Please share** how this access benefits you. Your story matters.

**Citation:** Bradley, Jill L. "Ultra-High-Resolution Optical Coherence Tomographic Findings in Commotio Retinae<alt-title>Ultra-High-Resolution OCT in Commotio Retinae</alt-title>." Archives of Ophthalmology 129.1 (2011): 106.

**As Published:** <http://dx.doi.org/10.1001/archophthalmol.2010.342>

**Publisher:** American Medical Association

**Persistent URL:** <http://hdl.handle.net/1721.1/71927>

**Version:** Author's final manuscript: final author's manuscript post peer review, without publisher's formatting or copy editing

**Terms of use:** Creative Commons Attribution-Noncommercial-Share Alike 3.0



Published in final edited form as:

*Arch Ophthalmol.* 2011 January ; 129(1): 107–108. doi:10.1001/archophthalmol.2010.342.

## Ultra–High-Resolution Optical Coherence Tomographic Findings in Commotio Retinae

Jill L. Bradley, BS, Sumit P. Shah, MD, Varsha Manjunath, BS, James G. Fujimoto, PhD, Jay S. Duker, MD, and Elias Reichel, MD

New England Eye Center, Tufts Medical Center, Boston (Mss Bradley and Manjunath and Drs Shah, Duker, and Reichel) and Massachusetts Institute of Technology, Cambridge (Dr Fujimoto)

Commotio retinae is a self-limited opacification of the retina secondary to direct blunt ocular trauma. Histologic studies of monkeys and humans relate this clinical observation to damaged photoreceptor outer segments and receptor cell bodies.<sup>1–3</sup> Reports using time-domain optical coherence tomography (OCT) and spectral-domain OCT support the involvement of the photoreceptor layer, but these techniques lack the resolution necessary to confirm results of histologic analysis.<sup>4–6</sup> Prototype high-speed ultra–high-resolution OCT (hs-UHR-OCT) images demonstrate these anatomical changes in a patient with acute commotio retinae.

### Report of a Case

A 46-year-old man visited the emergency department with pain and blurry vision in the right eye after blunt ocular trauma. Uncorrected visual acuities were 20/30 OD and 20/25 OS. External examination showed periorbital ecchymosis and laceration. Pupil examination results were normal with relative afferent pupillary defect. Intraocular pressures were 14 mm Hg OD and 13 mm Hg OS. Slitlamp examination revealed a subconjunctival hemorrhage in the right eye. Orbital computed tomography demonstrated fracture of the right inferior and medial orbital walls. Dilated examination of the right eye showed a central, annular area of opacification of the retina surrounding the fovea consistent with commotio retinae (Figure 1). Retinal imaging was performed using spectral-domain OCT (Cirrus HD-OCT, software version 3.0; Carl Zeiss Meditec, Dublin, California) and prototype hs-UHR-OCT.

### Comment

The spectral-domain OCT image suggests hyperreflectivity at the level of the photoreceptors (Figure 2A). However, the hs-UHR-OCT image better demonstrates increased backscattering at the level of the outer photoreceptor layer, with an obscuration of the inner segment–outer segment junction of the photoreceptor layers and hyperreflectivity of the retinal pigment epithelial layer (Figure 2C).

Improved visualization of these changes is likely owing to the greater axial resolution of the hs-UHR-OCT at 3.5  $\mu\text{m}$  compared with the 5- $\mu\text{m}$  axial resolution of the spectral-domain OCT as well as denser A-scan acquisition by the hs-UHR-OCT. The hs-UHROCT uses a

© 2011 American Medical Association. All rights reserved.

**Correspondence:** Dr Shah, New England Eye Center, Tufts Medical Center, 800 Washington St, Box 450, Boston, MA 02111 (shahsp1@gmail.com).

**Financial Disclosure:** Dr Duker receives research support from Carl Zeiss Meditec, Optovue, and Topcon Medical Systems. Dr Fujimoto receives royalties from Carl Zeiss Meditec and has stock options in Optovue.

broader bandwidth light source to achieve higher axial resolution. Normal internal controls of the left eye (Figure 2B and D) are included for comparison.

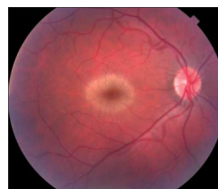Retinal disruption in commotion retinæ is demonstrated at the level of the outer and inner photoreceptor layers and retinal pigment epithelial layer using prototype hs-UHR-OCT. These in vivo findings are consistent with results of previous histologic studies of commotio retinæ.<sup>1-3</sup>

## Acknowledgments

**Funding/Support:** This work was supported in part by a Challenge grant to the New England Eye Center and Department of Ophthalmology, Tufts University School of Medicine from Research to Prevent Blindness, by contracts RO1-EY11289-23 and RO1-EY13178-07 from the National Institutes of Health, by grants FA9550-07-1-0101 and FA9550-07-1-0014 from the Air Force Office of Scientific Research, and by the Lions Club of Massachusetts.

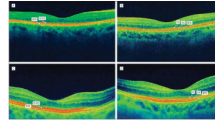
## References

1. Sipperley JO, Quigley HA, Gass DM. Traumatic retinopathy in primates: the explanation of commotio retinæ. *Arch Ophthalmol.* 1978; 96(12):2267–2273. [PubMed: 718521]
2. Mansour AM, Green WR, Hogge C. Histopathology of commotio retinæ. *Retina.* 1992; 12(1):24–28. [PubMed: 1565867]
3. Liem AT, Keunen JE, van Norren D. Reversible cone photoreceptor injury in commotio retinæ of the macula. *Retina.* 1995; 15(1):58–61. [PubMed: 7754249]
4. Sony P, Venkatesh P, Gadaginamath S, Garg SP. Optical coherence tomography findings in commotio retina. *Clin Experiment Ophthalmol.* 2006; 34(6):621–623. [PubMed: 16925718]
5. Meyer CH, Rodrigues EB, Mennel S. Acute commotio retinæ determined by cross-sectional optical coherence tomography. *Eur J Ophthalmol.* 2003; 13(9–10):816–818. [PubMed: 14700108]
6. Ismail R, Tanner V, Williamson TH. Optical coherence tomography imaging of severe commotio retinæ and associated macular hole. *Br J Ophthalmol.* 2002; 86(4):473–474. [PubMed: 11914221]



**Figure 1.**

Color fundus photograph of the right eye showing annular opacification surrounding the macula of commotio retinae after blunt trauma. Corresponding spectral-domain and ultra-high-resolution optical coherence tomographic images are shown in Figure 2A and C.



**Figure 2.**

Optical coherence tomographic (OCT) images. IS indicates inner segment; OS, outer segment; and RPE, retinal pigment epithelium. A, A spectral-domain OCT image of the right eye showing acute commotio retinae. B, A spectral-domain OCT image of a normal internal control (the left eye). C, A high-speed ultra-high-resolution OCT image showing higher-resolution disruption between the IS and OS photoreceptor layers and the RPE. D, A high-speed ultra-high-resolution OCT image of a normal internal control (the left eye).