

## MIT Open Access Articles

*Effects of the Combination of Microfracture and Self-Assembling Peptide Filling on the Repair of a Clinically Relevant Trochlear Defect in an Equine Model*

The MIT Faculty has made this article openly available. **Please share** how this access benefits you. Your story matters.

**Citation:** Miller, R. E., A. J. Grodzinsky, M. F. Barrett, H.-H. Hung, E. H. Frank, N. M. Werpy, C. W. McIlwraith, and D. D. Frisbie. "Effects of the Combination of Microfracture and Self-Assembling Peptide Filling on the Repair of a Clinically Relevant Trochlear Defect in an Equine Model." *The Journal of Bone & Joint Surgery* 96, no. 19 (October 1, 2014): 1601–1609. © 2014 by The Journal of Bone and Joint Surgery, Incorporated

**As Published:** <http://dx.doi.org/10.2106/jbjs.m.01408>

**Publisher:** Journal of Bone and Joint Surgery, Inc

**Persistent URL:** <http://hdl.handle.net/1721.1/90920>

**Version:** Final published version: final published article, as it appeared in a journal, conference proceedings, or other formally published context

**Terms of Use:** Article is made available in accordance with the publisher's policy and may be subject to US copyright law. Please refer to the publisher's site for terms of use.



# Effects of the Combination of Microfracture and Self-Assembling Peptide Filling on the Repair of a Clinically Relevant Trochlear Defect in an Equine Model

Rachel E. Miller, PhD, Alan J. Grodzinsky, ScD, Myra F. Barrett, MS, DVM, Han-Hwa Hung, BS, Eliot H. Frank, PhD, Natasha M. Werpy, DVM, C. Wayne McIlwraith, BVSc, PhD, and David D. Frisbie, DVM, PhD

Investigation performed at Colorado State University, Fort Collins, Colorado, and Massachusetts Institute of Technology, Cambridge, Massachusetts

**Background:** The goal of this study was to test the ability of an injectable self-assembling peptide (KLD) hydrogel, with or without microfracture, to augment articular cartilage defect repair in an equine cartilage defect model involving strenuous exercise.

**Methods:** Defects 15 mm in diameter were created on the medial trochlear ridge and debrided down to the subchondral bone. Four treatment groups (n = 8 each) were tested: no treatment (empty defect), only defect filling with KLD, only microfracture, and microfracture followed by filling with KLD. Horses were given strenuous exercise throughout the one-year study. Evaluations included lameness, arthroscopy, radiography, and gross, histologic, immunohistochemical, biochemical, and biomechanical analyses.

**Results:** Overall, KLD-only treatment of defects provided improvement in clinical symptoms and improved filling compared with no treatment, and KLD-only treatment protected against radiographic changes compared with microfracture treatment. Defect treatment with only microfracture also resulted in improved clinical symptoms compared with no treatment, and microfracture treatment resulted in repair tissue containing greater amounts of aggrecan and type-II collagen compared with KLD-only treatment. Microfracture treatment also protected against synovial fibrosis compared with no treatment and KLD-only treatment. Treatment with the self-assembling KLD peptide in combination with microfracture resulted in no additional improvements over microfracture-only treatment. In general, the nature of the predominant tissue in the defects was a mix of noncartilaginous and fibrocartilage tissue, with no significant differences among the treatments.

**Conclusions:** Treatment of defects with only KLD or with only microfracture resulted in an improvement in clinical symptoms compared with no treatment; the improvement likely resulted from different causes depending on the treatment. Whereas microfracture improved the quality of repair tissue, KLD improved the amount of filling and protected against radiographic changes.

**Clinical Relevance:** Treatment of defects with only microfracture and with KLD only resulted in clinical improvements compared with untreated defects, despite differing with respect to the structural improvements that they induced.

**Peer Review:** This article was reviewed by the Editor-in-Chief and one Deputy Editor, and it underwent blinded review by two or more outside experts. The Deputy Editor reviewed each revision of the article, and it underwent a final review by the Editor-in-Chief prior to publication. Final corrections and clarifications occurred during one or more exchanges between the author(s) and copyeditors.

Articular cartilage defects affect up to 10% to 12% of the population and, once they become symptomatic, rarely improve without treatment<sup>1</sup>. Marrow stimulation tech-

niques, particularly microfracture, remain the primary treatment option because of their minimal invasiveness and low cost<sup>2,3</sup>. Despite the short-term improvement noted in several

**Disclosure:** One or more of the authors received payments or services, either directly or indirectly (i.e., via his or her institution), from a third party in support of an aspect of this work. In addition, one or more of the authors, or his or her institution, has had a financial relationship, in the thirty-six months prior to submission of this work, with an entity in the biomedical arena that could be perceived to influence or have the potential to influence what is written in this work. Also, one or more of the authors has a patent or patents, planned, pending, or issued, that is broadly relevant to the work. No author has had any other relationships, or has engaged in any other activities, that could be perceived to influence or have the potential to influence what is written in this work. The complete **Disclosures of Potential Conflicts of Interest** submitted by authors are always provided with the online version of the article.

microfracture studies, long-term results have been mixed, especially for larger lesions<sup>2,4,5</sup>. Microfracture repair tissue tends to be more fibrocartilaginous, with inferior biochemical and biomechanical properties compared with normal hyaline cartilage<sup>2,6,7</sup>. Therefore, the investigation of alternatives and augments to microfracture continues to be an important area of study.

Noncellular matrices have been investigated as augments to microfracture<sup>4,6</sup>. Of these, self-assembling peptides represent an attractive option for designing matrices that encourage cellular recruitment. The sequences (RADA)<sub>4</sub> and (KLDL)<sub>3</sub> (referred to as KLD herein) support the chondrocyte phenotype<sup>8</sup> and bone marrow stromal cell chondrogenesis<sup>9-11</sup>. These peptides can be injected as a liquid and rapidly assemble when exposed to physiological pH and ionic strength<sup>12</sup>. A recent rabbit study showed superior healing in critically sized full-thickness cartilage defects treated with KLD compared with empty defects over twelve weeks<sup>13</sup>. In this small animal model, the full-thickness defect provided access to the marrow, suggesting that combining KLD with microfracture may offer an improvement over current practice.

The goal of the present study was to test the ability of KLD to augment cartilage defect repair with or without microfracture in an equine model involving strenuous exercise. Microfracture was chosen as the route for marrow access in the horse as it is the clinical gold standard treatment. Untreated defects and defects treated with only microfracture were used as controls.

## Materials and Methods

### Animals

The study was approved by the Animal and Care Use Committee at Colorado State University and utilized sixteen skeletally mature horses (two to five years of age) free of musculoskeletal disease. Horses were housed in 15-m<sup>2</sup> stalls, and the degree of postoperative exercise was controlled unless otherwise noted (see Appendix).

### Study Design

One 15-mm-diameter defect was created in each femoropatellar joint (two defects per horse), and defects were randomly assigned to one of four treatment groups: no treatment, defect filling with KLD, performance of microfracture, and performance of microfracture followed by filling with KLD. In eight of the horses, an empty defect was paired with a KLD-treated defect, varying the treatment placement between left and right knees. Similarly, in the other eight horses, defects treated with microfracture were paired with defects treated with microfracture followed by KLD filling, varying the placement between left and right knees. These pairings were chosen on the basis of experience with horse-to-horse variation in the response to microfracture<sup>14-16</sup>.

### KLD Peptide

KLD peptide constructs were developed as described previously<sup>13</sup>. In brief, KLD peptide (AcN-[KLDL]<sub>3</sub>-CNH<sub>2</sub>) was synthesized by the MIT Biopolymers Laboratory (Cambridge, Massachusetts) with use of a peptide synthesizer (ABI 433A; Applied Biosystems, Foster City, California) with FMOC (fluorenylmethyloxycarbonyl) protection. The KLD was resuspended at 3.5 mg/mL in sterile water.

### Defect Creation and Treatments

A femoropatellar arthrotomy was performed bilaterally under general anesthesia. A 15-mm-diameter impression was made in the articular cartilage of the medial trochlear ridge, and a curet was used to remove cartilage down to subchondral bone, with the subchondral bone plate left intact. If the defect was assigned to one of the microfracture treatment groups, standard subchondral bone microfracture

was performed<sup>14</sup>. If the defect was assigned to one of the KLD treatment groups, direct pressure was applied with a surgical sponge to ensure that all bleeding was stopped prior to application of the peptide, which was then delivered as a liquid peptide suspension. The liquid could easily be seen as it filled the defect, and the defect was filled until visually full. Lactated Ringer solution was then added to the joint periphery to cause polymerization of the peptide, which was visually inspected to ensure retention. If the defect was not assigned to a microfracture or KLD treatment group, it was left untreated and empty. The incision was closed in four successive layers (the joint capsule, deep and superficial fascia, and skin).

### Exercise

Horses were subjected to strenuous exercise (see Appendix) as described previously<sup>17</sup>.

### Clinical Evaluation

Examinations were performed before defect creation and approximately every four weeks until twelve months (immediately before euthanasia) with use of a published grading scale<sup>17</sup>. In brief, lameness as an indicator of pain in the limb was graded as 0 to 5, pain after flexion of the stifle joint was graded as 0 to 4, static range of motion of the knee (stifle) was graded as 0 to 4, and synovial effusion in the femoropatellar joint was graded as 0 to 4, with 0 representing normal.

### Arthroscopy

Defects were assessed arthroscopically by two surgeons blinded to treatment at six and twelve months after implantation (see Appendix).

### Radiographic Evaluation

Four standard radiographic views were evaluated by a board-certified radiologist blinded to treatment. Osseous sclerosis adjacent to the defect site, osseous lysis adjacent to the defect site, and osteophytosis were graded as 0 = normal, 1 = slight, 2 = mild, 3 = moderate, and 4 = severe. Defect filling was graded as 0 = none, 1 = 1% to 25%, 2 = 26% to 50%, 3 = 51% to 75%, and 4 = 76% to 100%. Radiographs were evaluated at baseline, one, twelve, forty, and fifty-two weeks after surgery.

### Postmortem Examination

Following euthanasia at twelve months after surgery, a necropsy that included examination of the femoropatellar joints was performed<sup>18</sup>. In brief, gross macroscopic observations were made to assess the overall condition of the joint, the color and integrity of the defect, and attachment of the repair tissue to surrounding bone and cartilage. Core biopsies of repair and native tissue were performed (Fig. 1).

### Magnetic Resonance Imaging (MRI)

Each femoropatellar joint was assessed immediately after euthanasia but before the joint was opened. Images were obtained with a 1.5-T GE Signa scanner (GE Medical Systems, Waukesha, Wisconsin). Proton density sequences with and without fat suppression and T2-weighted fast-spin-echo sequences were used in the sagittal, frontal, and transverse planes with 3-mm-thick slices. Images were assessed by a board-certified radiologist blinded to treatment as described previously<sup>16</sup> (see Appendix).

### Histologic Evaluation of Synovial Membrane

A synovial membrane sample from each stifle was fixed with formalin, embedded in paraffin, sectioned (5 μm), and stained with hematoxylin and eosin. Samples were evaluated for cellular infiltration, intimal hyperplasia, subintimal edema, subintimal fibrosis, and vascularity. Each category was graded with use of a scale from 0 (normal) to 4 (severe) as described previously<sup>18</sup>.

### Histologic and Immunohistochemical Evaluation of Repair Tissue

Defect sites were sectioned to produce 3-mm-wide proximal and distal sections for either histologic or immunohistochemical evaluation (Fig. 1). Histologic samples underwent formalin fixation for forty-eight hours followed by

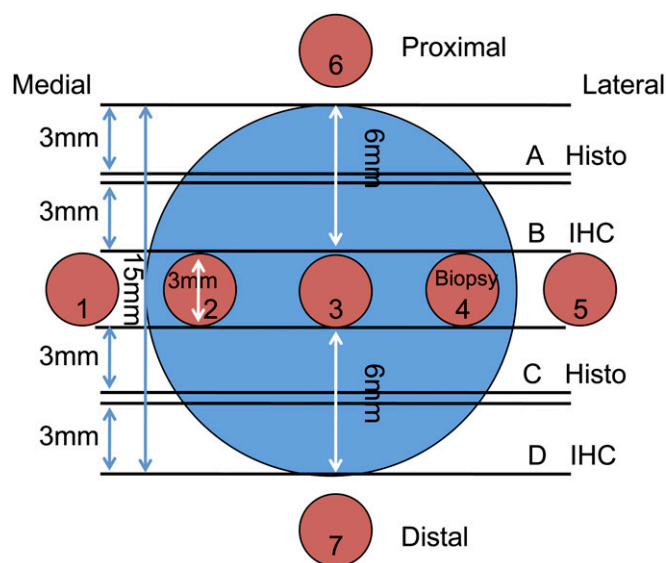


Fig. 1  
Schematic illustration of core biopsy sample collection for histologic (A and C), immunohistochemical (IHC) (B and D), biochemical (1 through 7), and biomechanical (1 through 7) evaluations of repair tissue (2, 3, and 4) and surrounding native tissue (1, 5, 6, and 7).

decalcification and paraffin embedding. Paraffin samples were sectioned (5  $\mu\text{m}$ ) and stained with hematoxylin and eosin. Slides were graded in a blinded fashion to evaluate repair tissue with use of a modified O'Driscoll grading system (see Appendix)<sup>13,18</sup>. Additionally, the percentage of granulation tissue present was estimated.

Immunohistochemical samples were frozen in embedding media and sectioned (8  $\mu\text{m}$ ). Sections for aggrecan detection were incubated in chondroitinase ABC (Sigma-Aldrich, St. Louis, Missouri) for fifteen minutes. Each sample underwent blocking with normal goat serum (Jackson Immuno-Research Laboratories, West Grove, Pennsylvania) followed by incubation in primary antibody solution of aggrecan (1:20; Acris Antibodies, San Diego, California), type-I collagen (1:100; Accurate Chemical & Scientific, Westbury, New York), or type-II collagen (undiluted; Developmental Studies Hybridoma Bank, Iowa City, Iowa), then incubated with anti-mouse-HRP (horseradish peroxidase) secondary antibody. Antigen detection involved visualization with ImmPACT NovaRED detection reagent (Vector Laboratories, Burlingame, California) and counterstaining with Fast Green. IgG (immunoglobulin G) controls gave no signal. Slides were graded in a blinded fashion to evaluate the percentage of defect stained compared with control tissue (0 = 0%, 1 = 1% to 25%, 2 = 26% to 50%, 3 = 51% to 75%, and 4 = 76% to 100%).

### Biomechanics

Up to three repair tissue samples and four native tissue samples from each joint were tested (Fig. 1). Cartilage-bone biopsy samples were thawed in PBS (phosphate buffered saline solution) with protease inhibitors, and cartilage plugs of uniform geometry (>0.5 mm thick) were cut. Dynamic stiffness was measured in unconfined compression with use of a Dynastat mechanical spectrometer (IMASS, Hingham, Massachusetts)<sup>19</sup>. A 15% offset strain was applied by means of three 5% ramp-and-hold steps (5% strain applied over sixty seconds, followed by a four-minute hold), and this was followed by a frequency sweep with 0.5% amplitude sinusoidal strains at 0.05, 0.1, 0.3, 0.5, 1.0, and 5.0 Hz. Dynamic compressive stiffness was calculated as the ratio of the fundamental amplitudes of the stress and strain. Equilibrium compressive stiffness was calculated from linear regression of equilibrium stress versus strain. The dynamic shear modulus was measured by application of a simple shear strain to each plug immediately after compressive stiffness testing<sup>20</sup>. Discs

underwent 15% and 30% axial compression followed by a frequency sweep of 1.5% amplitude sinusoidal shear strains from 0.05 to 1 Hz.

### Glycosaminoglycan (GAG) content

Following the biomechanical testing, cartilage plugs were weighed wet and digested in protease K solution. The total content of sulfated GAG was determined by DMMB (1,9-dimethylmethylene blue) dye binding as described previously<sup>21</sup> and is reported on the basis of the wet weight.

### Statistical Analysis

On the basis of previous studies<sup>17,18</sup>, eight defects per treatment were utilized to provide a power of >80% at  $\alpha = 0.05$ <sup>22</sup>. Data were analyzed with use of an ANOVA (analysis of variance) framework with the GLIMMIX procedure in SAS software (version 9.2; SAS Institute, Cary, North Carolina), with the horse as a random variable. Main effects were treatment, week, location (distal or proximal), or tissue type (native or repair). When the main effect or an interaction had a p value that was considered to be significant (<0.05) or indicate a trend (0.05 to <0.10), individual comparisons were made with use of the least square means procedure. All data are presented as the mean and the standard error. Nonparametric analyses were also performed when appropriate and yielded similar conclusions. Because the analyzed biologic outcome parameters represent a continuum rather than defined categories, the results of the parametric analysis are presented.

### Source of Funding

Funding was received from NIH-NIBIB (National Institutes of Health-National Institute of Biomedical Imaging and Bioengineering) grants EB003805 and AR060331, NDSEG (National Defense Science and Engineering) and NSF (National Science Foundation) graduate fellowships, and an ORS (Orthopaedic Research Society) travel award.

## Results

### Clinical Evaluations

When treatment groups were compared across the fifty-two-week study period, lameness scores were significantly poorer if defects received no treatment (mean for all time points,  $1.40 \pm 0.06$ ) compared with microfracture-only treatment ( $1.22 \pm 0.06$ ) or KLD-only treatment ( $1.18 \pm 0.06$ ) ( $p = 0.04$ ). There were no significant differences among the treatments at any individual time point. Overall, flexion scores were poorer if defects received no treatment ( $1.74 \pm 0.06$ ) compared with KLD-only treatment ( $1.52 \pm 0.06$ ) ( $p = 0.02$ ).

Averaged across treatment conditions, synovial effusion peaked at week twenty-four with scores of mild to moderate, then partially resolved to scores of slight to mild by week fifty-two ( $p < 0.0001$ ). At week twenty-four, synovial effusion was greater in untreated joints ( $3.12 \pm 0.20$ ) and joints treated with only KLD ( $2.99 \pm 0.20$ ) compared with only microfracture ( $1.88 \pm 0.20$ ) or microfracture plus KLD ( $1.76 \pm 0.20$ ) ( $p < 0.0001$ ). By week fifty-two, synovial effusion had partially abated in joints with no treatment ( $1.62 \pm 0.20$ ) and with KLD-only treatment ( $1.37 \pm 0.20$ ); effusion in the latter group was significantly less than that in joints treated with only microfracture ( $2.01 \pm 0.20$ ) ( $p < 0.0001$ ).

Static range of motion at week twenty-four was poorer in untreated joints ( $2.59 \pm 0.21$ ) compared with joints treated with only microfracture ( $1.53 \pm 0.21$ ) or with microfracture plus KLD ( $1.41 \pm 0.21$ ) ( $p = 0.0006$ ). There were no differences in range of motion among the groups by week fifty-two.

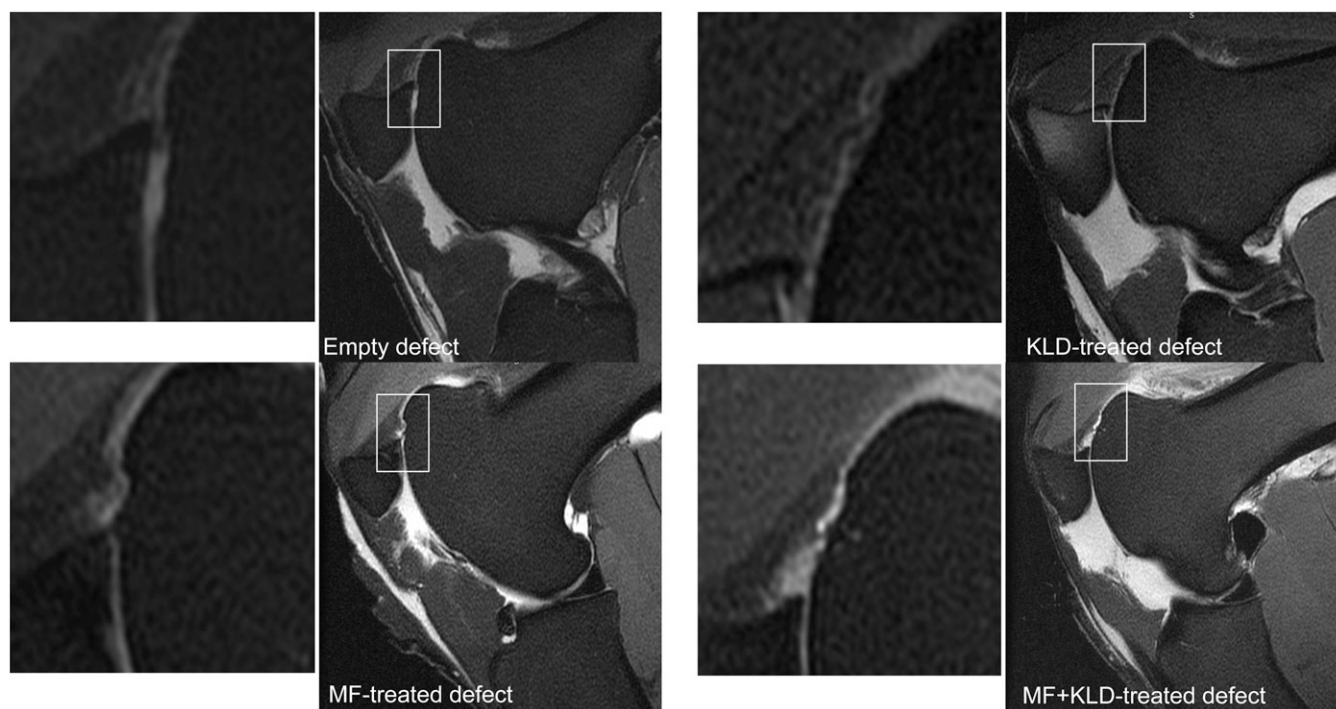


Fig. 2  
Representative MRI results (proton-density fat-saturated). Defects treated with only KLD had greater filling ( $2.25 \pm 0.40$ ) compared with untreated defects ( $1.00 \pm 0.40$ ) ( $p = 0.06$ ) but not compared with defects treated with only microfracture (MF) ( $1.63 \pm 0.40$ ) or with microfracture plus KLD ( $1.50 \pm 0.40$ ). The box surrounding each defect location indicates the location of the corresponding zoomed inset image.

### Arthroscopy

Averaged across the groups, cartilage attachment, bone attachment, and firmness were improved by week fifty-two compared with week twenty-four ( $p = 0.0999$ ,  $p = 0.03$ , and  $p = 0.04$ , respectively); the results did not differ significantly according to treatment ( $p = 0.95$ ,  $p = 0.79$ , and  $p = 0.65$ , respectively). In contrast, across the groups, the shape of the defect and smoothness of the surface were poorer at week fifty-two ( $0.19 \pm 0.05$  and  $2.47 \pm 0.10$ , respectively) compared with week twenty-four ( $0.00 \pm 0.05$  and  $2.22 \pm 0.10$ ) ( $p = 0.001$  and  $p = 0.04$ , respectively). The shapes of defects treated with only microfracture ( $0.38 \pm 0.09$ ) and with microfracture plus KLD ( $0.38 \pm 0.09$ ) were poorer than those of untreated defects ( $0.00 \pm 0.09$ ) and defects treated with only KLD ( $0.00 \pm 0.09$ ) at week fifty-two ( $p = 0.01$ ).

By week fifty-two, the volume of repair tissue did not differ significantly according to treatment ( $p = 0.98$ ), but defects treated with microfracture plus KLD had the smallest amount of filling ( $40.63\% \pm 10.93\%$ ), followed by untreated defects ( $41.88\% \pm 10.93\%$ ), defects treated with only KLD ( $49.38\% \pm 10.93\%$ ), and defects treated with only microfracture ( $55.63\% \pm 10.93\%$ ). There were no differences across the time points or among the treatments in the remaining arthroscopic evaluation categories.

### MRI

No treatment ( $1.75 \pm 0.28$ ) and KLD-only treatment ( $2.13 \pm 0.28$ ) yielded greater femoropatellar joint capsule fibrosis compared with microfracture-only treatment ( $0.63 \pm 0.28$ ) and microfracture plus

KLD ( $0.63 \pm 0.28$ ) ( $p = 0.003$ ). Filling of defects treated with only KLD was greater than that of untreated defects ( $p = 0.06$ ) but did not differ significantly from that of defects treated with only microfracture or with microfracture plus KLD (Fig. 2). Femoropatellar joint effusion, femoropatellar synovial proliferation, and adjacent articular cartilage abnormalities were scored as mild to moderate but showed no differences among treatments. Femoropatellar joint capsule edema, subchondral bone sclerosis, and subchondral bone edema appeared normal and showed no differences among treatments.

### Radiographic Examination

All groups developed some sclerosis and lysis after surgery, with scores progressively worsening with time up to week fifty-two ( $p < 0.0001$ ). Across the fifty-two weeks, sclerosis was significantly greater for defects treated with only microfracture compared with the other treatments ( $p = 0.0007$ ), and sclerosis was also greater for defects treated with microfracture plus KLD compared with no treatment ( $p = 0.0007$ ) (Fig. 3-A). These differences were already apparent by week twelve after surgery, and they remained through week fifty-two ( $p = 0.0007$ ) (Fig. 3-B). Osteophyte development was graded as slight in defects treated with only microfracture ( $0.40 \pm 0.14$ ) and with microfracture plus KLD ( $0.40 \pm 0.14$ ); defects that were untreated ( $0.00 \pm 0.14$ ) and those treated with only KLD ( $0.00 \pm 0.14$ ) appeared normal ( $p = 0.08$ ). Across the fifty-two-week period, defects treated with only microfracture ( $1.80 \pm 0.24$ ) and with microfracture plus KLD ( $1.73 \pm 0.24$ ) had



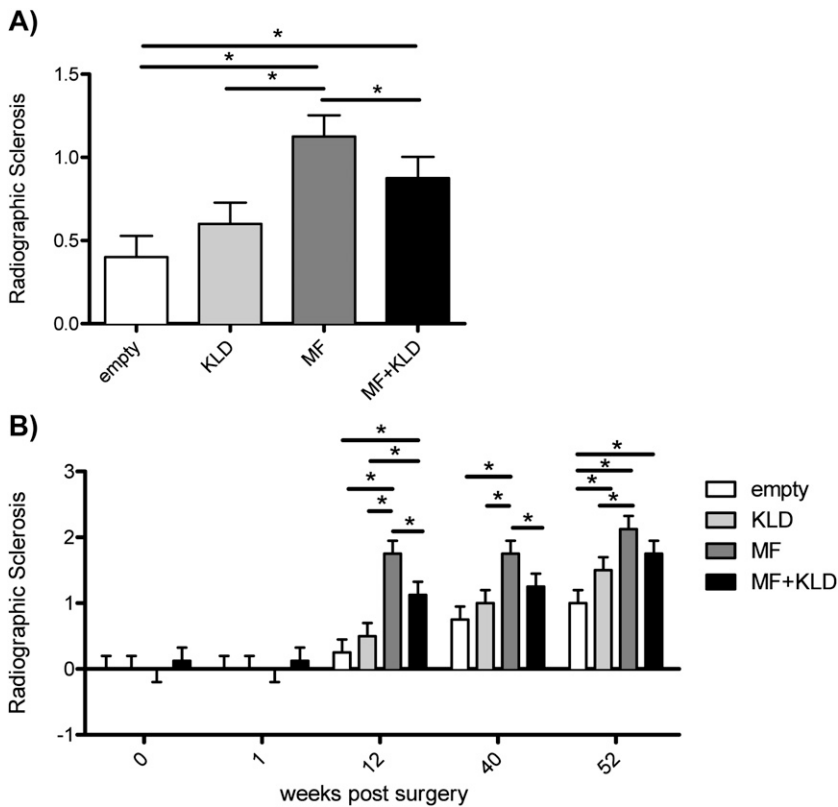


Fig. 3

Radiographically assessed sclerosis was greater in defects treated with only microfracture (MF) compared with untreated defects and defects treated with KLD only and with KLD plus microfracture, both across the fifty-two-week study period (**Fig. 3-A**) and at each time point beginning at twelve weeks after surgery (**Fig. 3-B**). Sclerosis was scored from 0 to 4, with 0 = normal, 1 = slight, 2 = mild, 3 = moderate, and 4 = severe. The values are shown as the mean and the standard error. \*P < 0.05.

poorer total radiographic scores compared with defects that were untreated ( $0.63 \pm 0.24$ ) and those treated with only KLD ( $0.85 \pm 0.24$ ) ( $p = 0.005$ ); scores averaged across the treatments worsened progressively after surgery ( $p < 0.0001$ ).

### Necropsy

None of the necropsy evaluation categories differed significantly among the groups. Overall, the outward appearance of the joints appeared normal, the extent of attachment of the repair tissue to the surrounding cartilage and bone was scored as mild, the repair tissue was mildly to moderately softer than the surrounding articular cartilage, and the overall grade of the repair tissue was fair. The volume of repair tissue was lowest in untreated defects ( $34.38\% \pm 11.40\%$ ), followed by defects treated with only microfracture ( $42.88\% \pm 11.40\%$ ), microfracture plus KLD ( $43.13\% \pm 11.40\%$ ), and only KLD ( $44.38\% \pm 11.40\%$ ), although these differences were not significant ( $p = 0.92$ ) (**Fig. 4**). Even though the volume differences did not reach significance, these rankings were consistent with the defect filling determined by MRI. MRI provides a more objective three-dimensional view of the repair tissue, which could explain why one of the filling differences determined by this method (between untreated defects and those treated with only KLD) achieved significance.

### Synovial Membrane

Defects treated with only KLD ( $2.88 \pm 0.33$ ) had greater subintimal fibrosis compared with defects treated with only microfracture ( $1.38 \pm 0.33$ ) ( $p = 0.04$ ). Slight to mild amounts of intimal

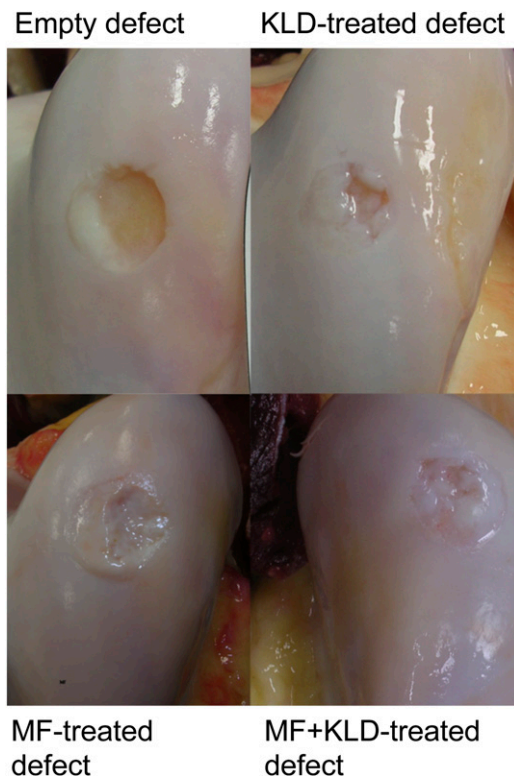


Fig. 4

Representative photographs of defects at the time of necropsy. MF = microfracture.

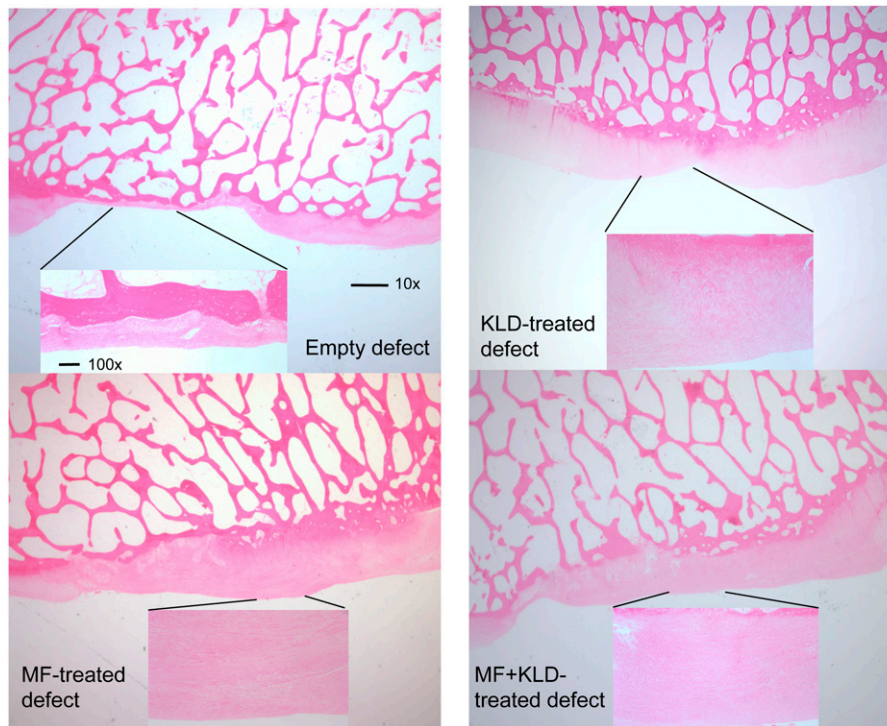


Fig. 5 Representative histologic image from each treatment group (hematoxylin and eosin). MF = microfracture. 10 $\times$  scale bar = 1 mm, and 100 $\times$  scale bar = 100  $\mu$ m.

hyperplasia and vascularity developed in the synovial membrane, but there were no differences among treatments. None of the groups developed cellular infiltration or subintimal edema.

### Histology

In general, the predominant tissue in the defects contained some fibrocartilage, but the repair tissue overall was mostly non-cartilaginous, with no significant differences among the treatments ( $p = 0.31$ ). In addition, there was some granulation-like tissue in the defects in all treatment groups, ranging from 2.5% to 10.6% of the repair tissue. Reconstitution of the subchondral bone appeared normal. Overall, the total histology score and bonding to adjacent cartilage were greater in the samples taken from the proximal side of the defect compared with the distal side (Fig. 1) ( $p = 0.003$ ,  $p = 0.006$ ), but there were no differences among the treatment groups (Fig. 5). Proximal tissue also had better structural integrity compared with distal tissue ( $p = 0.04$ ). Within proximal tissue, the structural integrity of defects treated with only microfracture was more normal than that of defects treated with only KLD or with microfracture plus KLD (Fig. 6) ( $p = 0.05$ ).

### Immunohistochemistry

Within distal tissue, defects treated with only microfracture had significantly more aggrecan than untreated defects; within proximal tissue, untreated defects and defects treated with only microfracture contained more aggrecan than defects treated with only KLD (Fig. 7-A) ( $p = 0.06$ ). Proximally and distally, defects treated with only microfracture had more type-II col-

lagen compared with defects treated with microfracture plus KLD and with only KLD. Proximally, untreated defects had more type-II collagen compared with defects treated with only KLD (Fig. 7-B) ( $p = 0.008$ ). All of the treatments resulted in similar amounts of type-I collagen filling the defects ( $p = 0.16$ ;

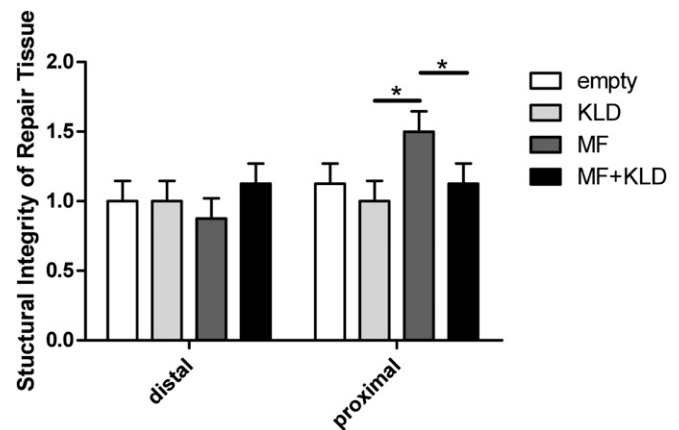


Fig. 6 Across the fifty-two-week study period, structural integrity of the proximal repair tissue was more normal for defects treated with only microfracture (MF) compared with only KLD and with microfracture plus KLD. Structural integrity was scored from 0 to 2, with 0 = severe disintegration, 1 = slight disruption, and 2 = normal. The values are shown as the mean and the standard error. \* $P < 0.05$ .

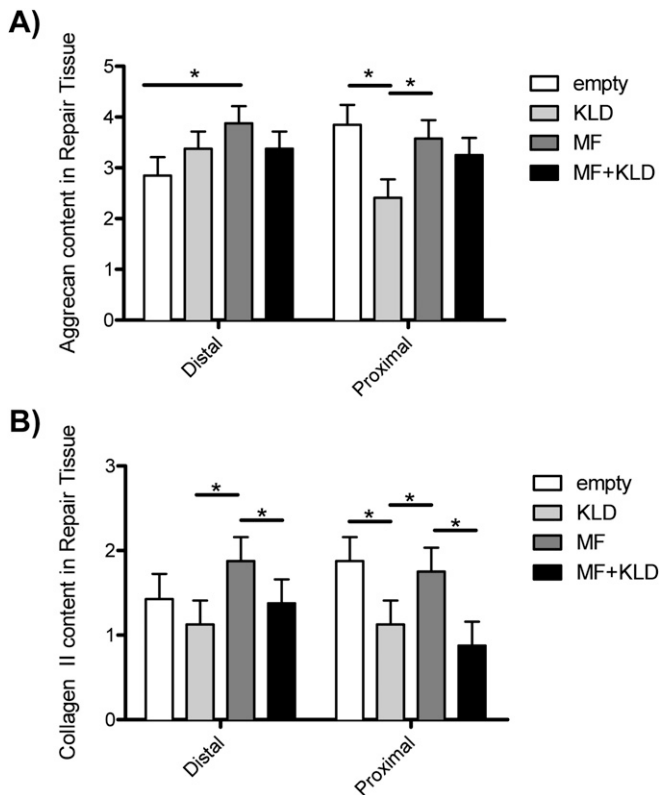


Fig. 7  
Across the fifty-two-week study period, aggrecan (Fig. 7-A) and type-II collagen (Fig. 7-B) contents in the distal repair tissue were greatest for microfracture (MF)-only treatment. On the proximal side, untreated defects and defects treated with only microfracture showed greater aggrecan and type-II collagen contents compared with defects treated with only KLD. The results were scored by comparing the percentage of defect stained compared with control tissue (0 = no staining, 1 = 1% to 25%, 2 = 26% to 50%, 3 = 51% to 75%, and 4 = 76% to 100%). The values are shown as the mean and the standard error. \* $P < 0.05$ .

treatment); overall, proximal tissue contained more type-I collagen than distal tissue ( $p = 0.04$ ).

### GAG

Native cartilage had approximately four times as much GAG compared with repair tissue, as measured by DMMB staining ( $p < 0.0001$ ). There were no differences in the GAG content of the repair tissue among the groups.

### Biomechanics

The dynamic, shear, and static stiffness of native cartilage were approximately ten times greater than those of repair tissue ( $p < 0.0001$ ). There were no differences in the biomechanics of the repair tissue among the groups.

### Discussion

Treatment of defects with KLD without microfracture provided some benefits with respect to clinical symptoms (16% improvement in lameness and 13% improvement in

flexion compared with no treatment). Similarly, treatment with microfracture without KLD filling provided some benefits (13% improvement in lameness and 41% improvement in range of motion at week twenty-four). However, treatment with a combination of microfracture plus KLD showed no additional benefits over either treatment alone. To our knowledge, this is the first experimental report of clinical improvements resulting from microfracture treatment, and it supports clinical trial results demonstrating short-term benefits with respect to knee function following microfracture<sup>5</sup>. In general, improvements of >10% warrant further investigation, with changes of >20% representing the goal for clinical treatments.

The improvement in clinical parameters seemed to result from different causes depending on the treatment. KLD-only treatment improved filling of the defect (as measured by MRI) compared with no treatment, and it resulted in fewer radiographic changes compared with microfracture treatment. In contrast, defect treatment with only microfracture resulted in repair tissue containing increased amounts of aggrecan and type-II collagen compared with treatment with only KLD. Microfracture-only treatment also protected against femoropatellar joint capsule fibrosis compared with no treatment and KLD-only treatment.

Across treatments, the defects in this study had poor repair, with <50% of the defect volume being filled and a high content of nonchondrocytic cells, including the presence of granulation-like tissue. These observations are in accordance with the low amount of GAG in repair tissue and with the low stiffness of the repair tissue, which remained an order of magnitude lower than that of the surrounding native cartilage. Despite poor cartilage repair, reconstitution of subchondral bone appeared normal.

The poor filling of untreated defects in this study was unusual compared with similar studies. In a 2008 study in which defects with the same size were created at a similar location (the trochlear groove), 60% filling of the defect was reported by twelve to eighteen months after surgery, as determined by histology<sup>17</sup>, compared with 34%, as determined at necropsy, in the present study. As in the present study, horses underwent strenuous exercise, but the calcified cartilage layer was left intact in the 2008 study. Although removal of the calcified cartilage is beneficial when performing microfracture<sup>23</sup>, it is possible that it hinders repair of untreated defects.

Previous equine studies have also evaluated defect filling after microfracture. Fortier et al. reported comparable levels of defect filling, as determined by MRI, at eight months after surgery in microfracture-treated defects of the same size and in a similar location as those in the present study<sup>24</sup>. In a different study utilizing strenuous exercise<sup>23</sup>, microfracture was performed on defects on the medial femoral condyle rather than the trochlear groove; greater filling, as determined by gross examination, was observed at twelve months after surgery ( $63\% \pm 7\%$  compared with  $42.88\% \pm 11.40\%$  in the present study). Although few microfracture studies in patients have specified results according to location, Kreuz et al. showed that patients reported less functional improvement over a three-year period following microfracture to treat trochlear or patellar defects compared with defects on the femoral condyles or tibia<sup>25,26</sup>. Although KLD-only treatment in



the present study improved clinical outcomes and defect filling compared with no treatment, the quality of the repair tissue remained poor. KLD-treated defects had decreased aggrecan and type-II collagen in the proximal side of the repair tissue compared with untreated defects. The combination of microfracture plus KLD resulted in no additional improvement over microfracture-only or KLD-only treatment, and it resulted in decreased type-II collagen compared with microfracture-only treatment. In a rabbit model, KLD-only treatment of full-thickness trochlear groove defects with marrow access resulted in markedly improved cartilage regeneration, as indicated by increases in the total histology score, safranin-O staining, and type-II collagen after twelve weeks compared with no treatment<sup>13</sup>. Therefore, it is possible that insufficient cellular and growth factor infiltration of the KLD occurred in the present study. We are presently studying the ability of functionalized scaffolds to deliver proanabolic factors (e.g., the heparin-binding form of insulin-like growth factor 1, HB-IGF-1<sup>27</sup>) and/or anticatabolic factors to a defect. It is also possible that the microfracture did not generate sufficient marrow flow for infiltration of the KLD. An example of a material that has successfully augmented microfracture healing is a chitosan-based polymer scaffold that has been reported to stabilize the blood clot during microfracture, resulting in improved lesion filling compared with microfracture-only treatment at twelve months<sup>28</sup>.

In conclusion, treatment of defects with only KLD or with only microfracture resulted in an improvement in clinical symptoms compared with no defect treatment, but the improvement appeared to result from different causes depending on the treatment.

## Appendix

**eA** Tables summarizing the exercise protocol and the arthroscopic, MRI, and histologic grading systems are available

with the online version of this article as a data supplement at [jbjs.org](http://jbjs.org). ■

Rachel E. Miller, PhD  
Department of Internal Medicine,  
Rush University Medical Center,  
1735 West Harrison Street,  
Room 553A,  
Chicago, IL 60612

Alan J. Grodzinsky, ScD  
Han-Hwa Hung, BS  
Eliot H. Frank, PhD  
Massachusetts Institute of Technology,  
77 Massachusetts Avenue,  
MIT NE47-377,  
Cambridge, MA 02139

Myra F. Barrett, MS, DVM  
C. Wayne McIlwraith, BVSc, PhD  
David D. Frisbie, DVM, PhD  
Department of Environmental and Radiological Health Sciences (M.F.B.)  
and Orthopaedic Research Center,  
Department of Clinical Sciences (C.W.M. and D.D.F.),  
College of Veterinary Medicine and Biological Sciences,  
Colorado State University,  
300 West Drake Road,  
Fort Collins, CO 80523.  
E-mail address for D.D. Frisbie: [david.frisbie@colostate.edu](mailto:david.frisbie@colostate.edu)

Natasha M. Werpy, DVM  
Department of Radiology,  
College of Veterinary Medicine,  
University of Florida,  
PO Box 100126,  
Gainesville, FL 32610

## References

- Sellards RA, Nho SJ, Cole BJ. Chondral injuries. *Curr Opin Rheumatol*. 2002 Mar;14(2):134-41. Epub 2002 Feb 15.
- Basad E, Ishaque B, Bachmann G, Stürz H, Steinmeyer J. Matrix-induced autologous chondrocyte implantation versus microfracture in the treatment of cartilage defects of the knee: a 2-year randomised study. *Knee Surg Sports Traumatol Arthrosc*. 2010 Apr;18(4):519-27. Epub 2010 Jan 12.
- Redler LH, Caldwell JM, Schulz BM, Levine WN. Management of articular cartilage defects of the knee. *Phys Sportsmed*. 2012 Feb;40(1):20-35. Epub 2012 Apr 18.
- Gomoll AH. Microfracture and augments. *J Knee Surg*. 2012 Mar;25(1):9-15. Epub 2012 May 26.
- Mithoefer K, McAdams T, Williams RJ, Kreuz PC, Mandelbaum BR. Clinical efficacy of the microfracture technique for articular cartilage repair in the knee: an evidence-based systematic analysis. *Am J Sports Med*. 2009 Oct;37(10):2053-63. Epub 2009 Feb 26.
- Strauss EJ, Barker JU, Kercher JS, Cole BJ, Mithoefer K. Augmentation strategies following the microfracture technique for repair of focal chondral defects. *Cartilage*. 2010 Mar;1(2):145-52.
- Krych AJ, Harnly HW, Rodeo SA, Williams RJ 3rd. Activity levels are higher after osteochondral autograft transfer mosaicplasty than after microfracture for articular cartilage defects of the knee: a retrospective comparative study. *J Bone Joint Surg Am*. 2012 Jun 6;94(11):971-8. Epub 2012 May 29.
- Kisiday J, Jin M, Kurz B, Hung H, Semino C, Zhang S, Grodzinsky AJ. Self-assembling peptide hydrogel fosters chondrocyte extracellular matrix production and cell division: implications for cartilage tissue repair. *Proc Natl Acad Sci U S A*. 2002 Jul 23;99(15):9996-10001. Epub 2002 Jul 15.
- Erickson IE, Huang AH, Chung C, Li RT, Burdick JA, Mauck RL. Differential maturation and structure-function relationships in mesenchymal stem cell- and chondrocyte-seeded hydrogels. *Tissue Eng Part A*. 2009 May;15(5):1041-52. Epub 2009 Jan 6.
- Kisiday JD, Kopesky PW, Evans CH, Grodzinsky AJ, McIlwraith CW, Frisbie DD. Evaluation of adult equine bone marrow- and adipose-derived progenitor cell chondrogenesis in hydrogel cultures. *J Orthop Res*. 2008 Mar;26(3):322-31. Epub 2007 Oct 26.
- Kopesky PW, Vanderploeg EJ, Sandy JS, Kurz B, Grodzinsky AJ. Self-assembling peptide hydrogels modulate in vitro chondrogenesis of bovine bone marrow stromal cells. *Tissue Eng Part A*. 2010 Feb;16(2):465-77. Epub 2009 Aug 27.
- Zhang S, Holmes T, Lockshin C, Rich A. Spontaneous assembly of a self-complementary oligopeptide to form a stable macroscopic membrane. *Proc Natl Acad Sci U S A*. 1993 Apr 15;90(8):3334-8. Epub 1993 Apr 15.
- Miller RE, Grodzinsky AJ, Vanderploeg EJ, Lee C, Ferris DJ, Barrett MF, Kisiday JD, Frisbie DD. Effect of self-assembling peptide, chondrogenic factors, and bone marrow-derived stromal cells on osteochondral repair. *Osteoarthritis Cartilage*. 2010 Dec;18(12):1608-19. Epub 2010 Sep 17.
- Frisbie DD, Trotter GW, Powers BE, Rodkey WG, Steadman JR, Howard RD, Park RD, McIlwraith CW. Arthroscopic subchondral bone plate microfracture technique augments healing of large chondral defects in the radial carpal bone and medial femoral condyle of horses. *Vet Surg*. 1999 Jul-Aug;28(4):242-55. Epub 1999 Jul 29.
- McIlwraith CW, Frisbie DD. Microfracture: basic science studies in the horse. *Cartilage*. 2010 Apr;1(2):87-95.
- McIlwraith CW, Frisbie DD, Rodkey WG, Kisiday JD, Werpy NM, Kawcak CE, Steadman JR. Evaluation of intra-articular mesenchymal stem cells to augment healing of microfractured chondral defects. *Arthroscopy*. 2011 Nov;27(11):1552-61. Epub 2011 Aug 20.

- 17.** Frisbie DD, Bowman SM, Colhoun HA, DiCarlo EF, Kawcak CE, Mcllwraith CW. Evaluation of autologous chondrocyte transplantation via a collagen membrane in equine articular defects: results at 12 and 18 months. *Osteoarthritis Cartilage*. 2008 Jun;16(6):667-79. Epub 2007 Nov 26.
- 18.** Frisbie DD, Lu Y, Kawcak CE, DiCarlo EF, Binette F, Mcllwraith CW. In vivo evaluation of autologous cartilage fragment-loaded scaffolds implanted into equine articular defects and compared with autologous chondrocyte implantation. *Am J Sports Med*. 2009 Nov;37(Suppl 1):71S-80S. Epub 2009 Dec 16.
- 19.** Treppo S, Koepp H, Quan EC, Cole AA, Kuettner KE, Grodzinsky AJ. Comparison of biomechanical and biochemical properties of cartilage from human knee and ankle pairs. *J Orthop Res*. 2000 Sep;18(5):739-48. Epub 2000 Dec 16.
- 20.** Frank EH, Jin M, Loening AM, Levenston ME, Grodzinsky AJ. A versatile shear and compression apparatus for mechanical stimulation of tissue culture explants. *J Biomech*. 2000 Nov;33(11):1523-7. Epub 2000 Aug 15.
- 21.** Farndale RW, Sayers CA, Barrett AJ. A direct spectrophotometric microassay for sulfated glycosaminoglycans in cartilage cultures. *Connect Tissue Res*. 1982;9(4):247-8. Epub 1982 Jan 1.
- 22.** Pearce GL, Frisbie DD. Statistical evaluation of biomedical studies. *Osteoarthritis Cartilage*. 2010 Oct;18(Suppl 3):S117-22. Epub 2010 Oct 1.
- 23.** Frisbie DD, Morisset S, Ho CP, Rodkey WG, Steadman JR, Mcllwraith CW. Effects of calcified cartilage on healing of chondral defects treated with microfracture in horses. *Am J Sports Med*. 2006 Nov;34(11):1824-31. Epub 2006 Jul 10.
- 24.** Fortier LA, Potter HG, Rickey EJ, Schnabel LV, Foo LF, Chong LR, Stokol T, Cheetham J, Nixon AJ. Concentrated bone marrow aspirate improves full-thickness cartilage repair compared with microfracture in the equine model. *J Bone Joint Surg Am*. 2010 Aug 18;92(10):1927-37. Epub 2010 Aug 20.
- 25.** Kreuz PC, Erggelet C, Steinwachs MR, Krause SJ, Lahm A, Niemeyer P, Ghanem N, Uhl M, Südkamp N. Is microfracture of chondral defects in the knee associated with different results in patients aged 40 years or younger? *Arthroscopy*. 2006 Nov;22(11):1180-6. Epub 2006 Nov 7.
- 26.** Kreuz PC, Steinwachs MR, Erggelet C, Krause SJ, Konrad G, Uhl M, Südkamp N. Results after microfracture of full-thickness chondral defects in different compartments in the knee. *Osteoarthritis Cartilage*. 2006 Nov;14(11):1119-25. Epub 2006 Jul 11.
- 27.** Florine E, Lee RT, Patwari P, Grodzinsky AJ. HB-IGF-1 adsorbed to self-assembling peptide enhances matrix production by encapsulated chondrocytes and co-cultured cartilage explants. Read at the 59th Annual Meeting of the Orthopaedic Research Society; 2013 Jan 26-29; San Antonio, TX. Paper no. 159.
- 28.** Stanish WD, McCormack R, Forriol F, Mohtadi N, Pelet S, Desnoyers J, Restrepo A, Shive MS. Novel scaffold-based BST-CarGel treatment results in superior cartilage repair compared with microfracture in a randomized controlled trial. *J Bone Joint Surg Am*. 2013 Sep 18;95(18):1640-50. Epub 2013 Sep 21.